

Uterine Leiomyoma: Hysterosalpingographic Appearances

Firoozeh Ahmadi, M.D.*, Fatemeh Zafarani, B.Sc., Maryam Niknejadi, M.D., Ahmad Vosough, M.D.

Reproductive Imaging Division, Endocrinology & Female Infertility Department, Reproductive Medicine Research Center, Royan Institute, ACECR, Tehran, Iran

Abstract

Uterine leiomyoma is the most common benign tumor of genital tract. The etiology of myomas is unknown. Leiomyoma shows a broad spectrum of radiographic appearances depending on the number, size, and location of the tumor. The diagnostic method for uterine leiomyomas is based primarily on the clinical situation. Despite of the varied diagnostic options such as; transvaginal sonography, sonohysterography, hysteroscopy, laparoscopy and MRI; hysterosalpingography is still one of the valuable imaging methods for identification of uterine leiomyoma.

The various features of the proved leiomyoma are illustrated in this pictorial review. The incidence, risk factors and clinical features will also be discussed briefly.

Keywords: Leiomyoma, Hysterosalpingographic Appearances

Introduction

Uterine leiomyomas or fibroids are the most common pelvic tumors of the female genital tract, occurring in 20–25% of reproductive-age women (1, 2). The reported incidence of myoma varies from 5.4 to 77% (the gold standard is histological evidence) depending on the studied population and the used diagnostic method (3, 4). The incidence of uterine leiomyomas increases as women grow older and they may occur in more than 30 percent of women between 40 to 60 years of age (5). Hysterosalpingography as a simple, less-invasive, more convenient and cost-effective imaging methods plays the major role in the early evaluation of infertile couple and provides reliable information about intrauterine lesions such as leiomyoma.

Diagnostic value of hysterosalpingography compared to hysteroscopy in detection of intrauterine abnormalities shows a sensitivity of 81.2% and a specificity of 80.4%, with a positive predictive value of 63.4% and a negative predictive value of 83.7% (6).

HSG is superior to hysteroscopy for a lesions penetrating into myometrium, congenital as well as acquired anomalies and for evaluation of the uterine scar (7).

This pictorial review illustrates a variety of hysterosalpingographic images produced by leiomyoma of uterus depending on their number, size, and location relative to the uterine cavity. These cases are approved by curettage and biopsy of the endometrium, hysteroscopy or laparoscopy.

Etiology/Risk factors

The etiology of myomas is unknown. Several studies have suggested that each leiomyoma arises from a single neoplastic cell within the smooth muscle of the

myometrium (8, 9). The involved factors include sex steroid hormones estrogen, progesterone, insulin-like growth factors, epidermal growth factor, and transforming growth factor. The risk factors include nulliparity, obesity, family history, black race, and hypertension (10-13). Based on ultrasound or hysterectomy diagnosis, the incidence of fibroids in black women is three times more than in white women (12, 13).

Recent evidence show that women with hypertension also have an increased incidence of fibroid tumors, possibly through smooth muscle injury or cytokine release (14).

Clinical features

Leiomyomas are usually asymptomatic, though they may present with acute symptoms that would require urgent treatment. Uterine leiomyoma are commonly identified in women who have menorrhagia, pelvic pain, obstructive symptoms, infertility, or pregnancy loss (15). The symptomatology and severity usually depends on the size, position and number of myomas.

Menorrhagia, is the most common symptom associated with uterine fibroid tumors, which is often caused by submucosal myoma (16). Pelvic pain and pressure are less commonly attributed to uterine fibroid tumors. Acute pain may result from torsion of a pedunculated leiomyoma or infarction and degeneration. Degenerative changes with necrosis, hemorrhage, and fibrosis is often accompanied by calcification.

The role of fibroid in infertility is controversial. Impaired gamete transport, distortion of the endometrium cavity, occlusion of intramural fallopian tube, impairment of blood supply to the endometrium and atrophy,

* Corresponding Address: P.O.Box: 19395-4644, Reproductive Imaging Division, Endocrinology & Female Infertility Department, Reproductive Medicine Research Center, Royan Institute, ACECR, Tehran, Iran
Email: fahmadi@royaninstitute.org



and ulceration might be responsible (17, 18). The possible role of fibroids in early miscarriage is also controversial. Increased uterine contractility or abnormal blood flow to fetus may lead to recurrent miscarriages (19).

During pregnancy myomas may increase markedly in size, whereas after menopause they stop growing and may regress. Leiomyosarcoma is a rare malignant neoplasm. The incidence of sarcomatous changes in benign uterine leiomyoma is reported to be between 0.13% and 0.81% (20-22).

Leiomyomas are classified by location into three types: intramural (most common), subserosal and submucosal (least common) (23). Most myomas originate within the myometrium of the body and fundus of the uterus. Infrequently, they involve the uterine ligaments, lower uterine segment, and cervix. The majority are embedded within the myometrial wall in an intramural location. When they occur beneath the peritoneal covering of the uterus, they are called subserosal. Myomas elevating endometrium and protruding into the uterine cavity are designated as submucosal. Both subserosal and submucosal fibroids may become pedunculated.

Diagnosis

The diagnostic method for uterine leiomyomas is based primarily on the clinical situation. Pelvic ultrasound is always the initial study in the evaluation of a pelvic mass. MRI is a highly accurate modality for differentiating leiomyomas in cases of enlarged uterus, with a reported accuracy of 99% (24, 25). In the younger patient and especially when myomectomy is planned to preserve childbearing capacity, a hysterosalpingogram is needed to determine the relationship of the myoma to the uterine cavity. Hysterosalpingography is also recommended when a myoma is suspected in these women with abnormal bleeding, infertility or recurrent abortion.

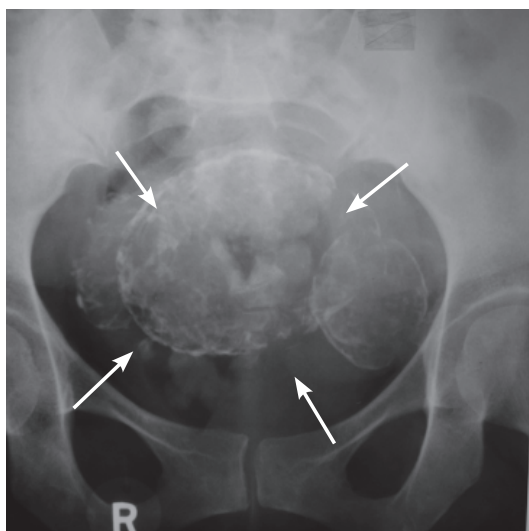


Fig 1: Plain film of the abdomen and pelvis shows the uterine leiomyoma (arrows).

Characteristics of Leiomyoma on Hysterosalpingography

Leiomyoma show a broad spectrum of radiographic appearances based on the number, size, and location of the tumor. A unique capability of myoma is to enlarge the uterine cavity markedly, probably relating to the intramural myoma. Sometimes, a large amount of contrast material exceeding 30 ml may be introduced into the cavity without complete filling. A myoma located in the cornual portion may cause a mechanical block and make it impossible to introduce contrast into the fallopian tubes. Plain radiography of the abdomen and pelvis often does not show the uterine leiomyoma unless the tumor has undergone calcified degeneration (Fig 1). This type of degenerate change is more common with subserosal lesions, especially tumors with pedicles and in leiomyomas in postmenopausal women.

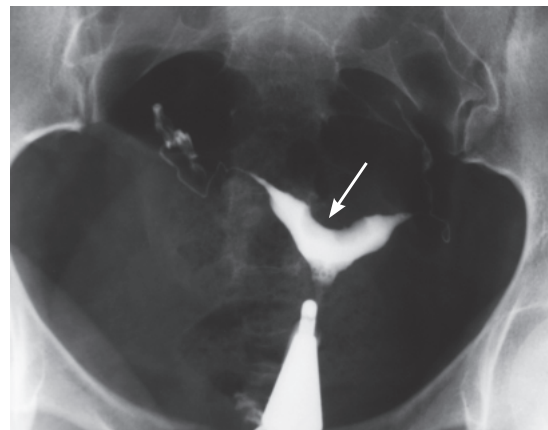


Fig 2: Smooth fundal submucosal leiomyoma giving a concavity in the central area (arrowed). The uterus simulates an arcuate uterus.

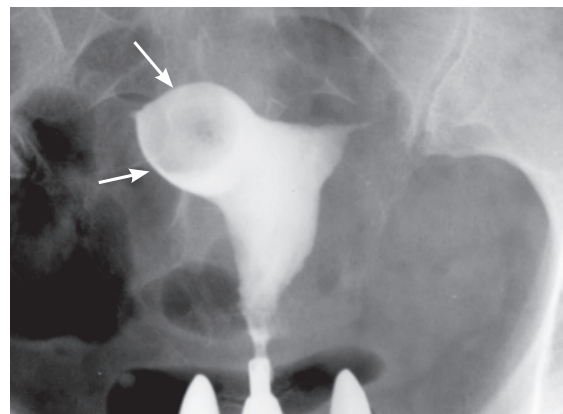


Fig 3: A submucosal myoma located on right cornu. Marked stretching and deformity of the right horn, and increasing the size of the right cornua are asymmetrically seen (arrowed).

Submucosal leiomyoma

Submucosal myoma is the least common, but most often accounts for symptoms. HSG is considered as the valuable method for identification of a submucosal leiomyoma. Submucosal myoma can be seen as smooth or

irregular, single or multiple, small or large filling defect (Fig 2-6). If the mass is large, there is simultaneous generalized enlargement of the uterine cavity.

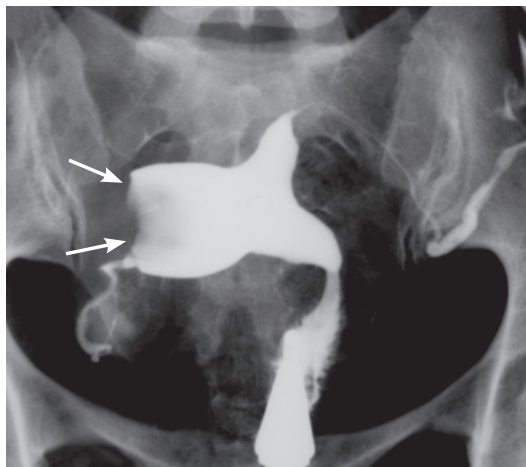


Fig 4: Localized enlargement and distortion of the right horn by a submucosal myoma (arrows). The distance between two cornuas has been increased.

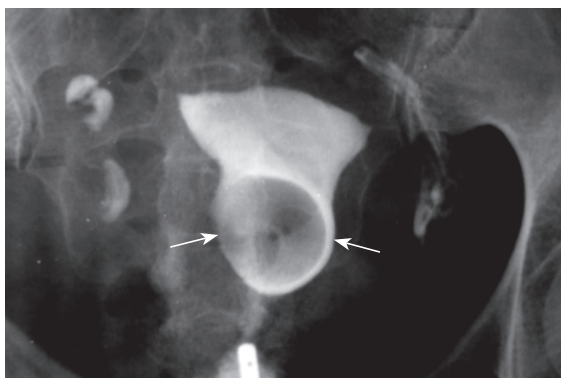


Fig 5: Leiomyoma located in lower segment of uterus distorting of the cavity (arrows).

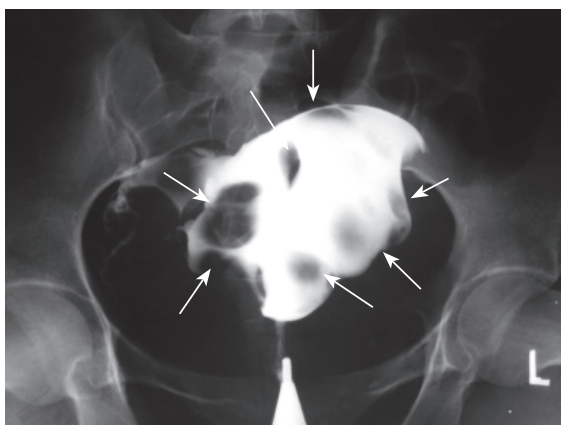


Fig 6: multiple submucosal myoma. Hysterosalpingogram shows an enlarged and distorted uterine cavity filled with multiple uterine myoma (arrows).

Attention to technique is important in the evaluation of

leiomyomas and they are easily seen as contrast first enters the uterus. The filling defect may be obscured by subsequent introduction of larger quantities of contrast (Fig 7A and B).

Small filling defects must be differentiated from air bubbles, endometrial polyp, blood clots, and retained products of conception (Fig 8, Fig 9A and B). Repositioning the patient or aspiration and refilling of the uterine cavity resolves problems with air bubbles.

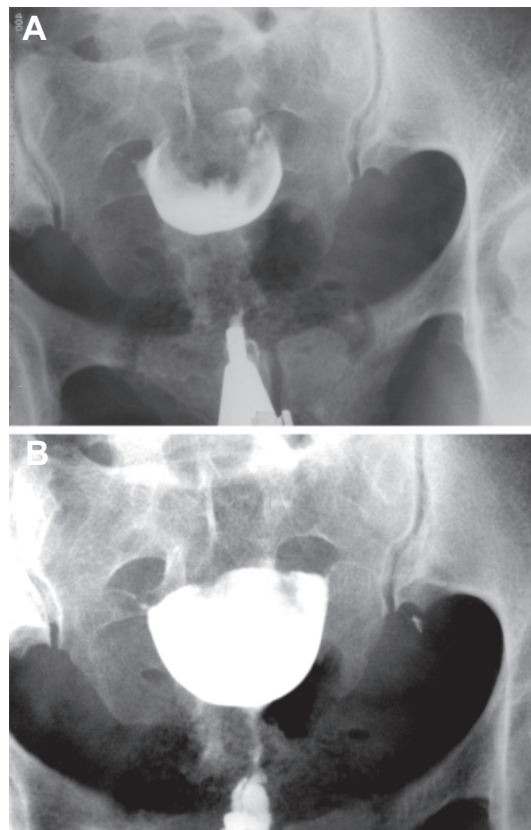


Fig 7: A: Marked distortion and deformation of the uterine cavity caused by a fundal myoma. The uterus resembles a bicornuate uterus due to excessive pressure of the tumor. B: Film taken after injection of larger amounts of contrast medium. The filling defect over shadowed by the excess of contrast medium.

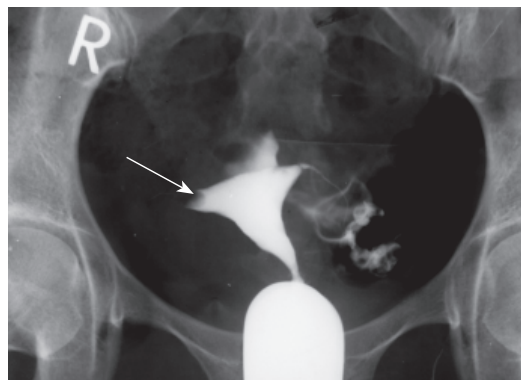


Fig 8: Radiolucent filling defect (arrow) in the right cornua due to air bubble. At first, Obstruction of the right tube was present. Subsequent films showed disappearance of this mobile lucenc.

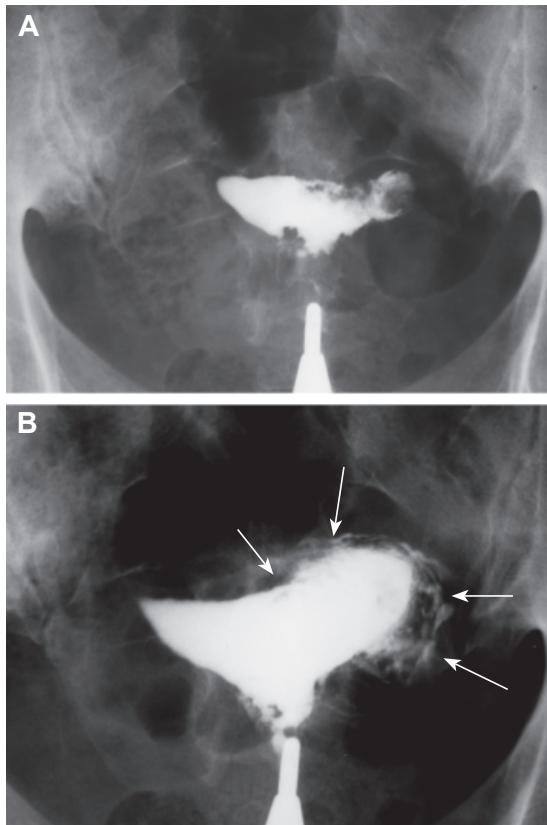


Fig 9: A: Multiple irregular filling defects in the right uterine cornua (arrows) representing retained products of pregnancy. B: The filling defect obscured by the excess of contrast medium. Intravasation of contrast is seen surrounding the left cornua (arrows). Performing a HSG shortly after endometrial instrumentation is causative.

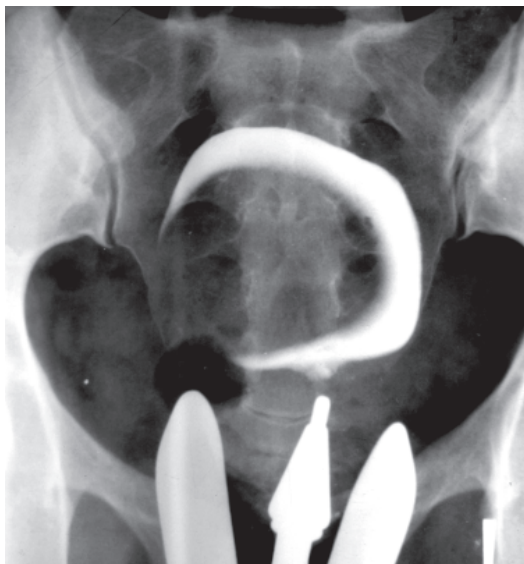

Fig 10: Early filling defect of the uterine cavity shows a large submucosal myoma. The uterine cavity has a globular shape and contrast medium surrounds the tumor.

Submucous myomas usually alter uterine contour and

size, whereas polyps are usually seen as a filling defect in an otherwise normal uterine cavity with smaller and more sharply outlined than submucosal fibroids, while blood clots and retained placenta have more angular outlines. Larger filling defects are generally caused by large submucous or intramural myoma with submucous components, and there may be associated with the enlargement and distortion of the endometrial cavity (Fig 10, Fig 11).

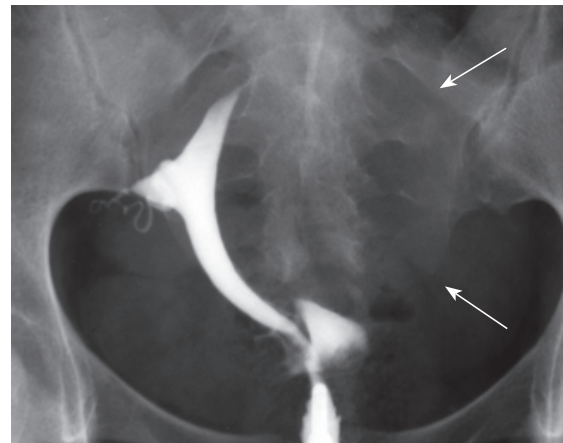


Fig 11: Marked enlargement, deformity and compression of the uterine cavity by an intramural myoma developing submucous component (arrows). The left tube is not visualized due to excessive pressure on left uterine wall by the tumor.

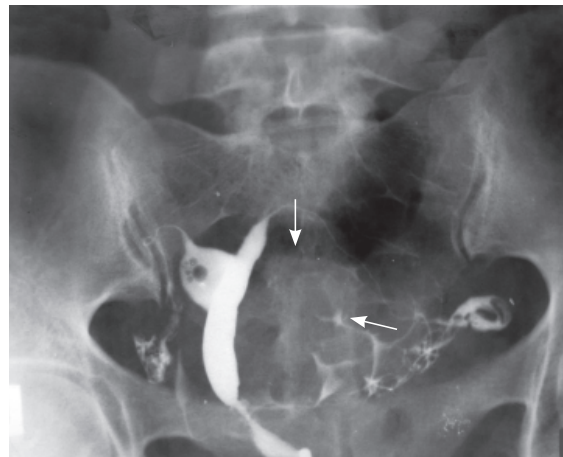


Fig 12: Marked enlargement, deformity and compression of the uterine cavity by an intramural myoma developing submucous component (arrows). The left tube is not visualized due to excessive pressure on left uterine wall by the tumor.

These lesions can adversely affect implantation of the fertilized ovum and may obstruct access to a tubal ostium, as well as cause uterine bleeding.

Intramural and subserosal leiomyoma

Intramural leiomyomas may displace, rotate, distort, and enlarge the endometrial cavity and in some cases, cause asymmetrical enlargement of the cavity (Fig 11-13).

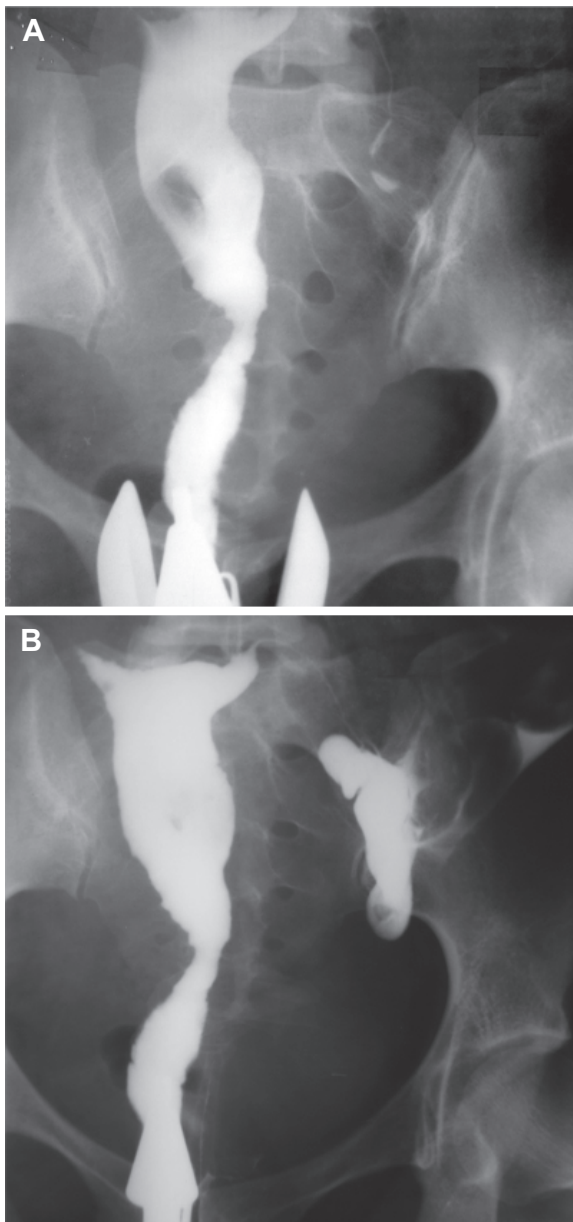


Fig 13: *A: The uterine cavity elongated by myoma. B: More than 30 ml of contrast medium was introduced into the cavity.*

Intramural cervical myoma produces a curved, distortion and elongation of the cervix (Fig 14). Subserosal myomas will not be apparent on hystero-grams unless they are large enough to cause obvious displacement of the uterus (Fig 15-18). The increase in size may be caused by hypotony of the uterine muscle, or it may be secondary to actual increased size of the uterus in response to the growing myoma (26) (Fig 19A, B). When enlargement is mild the volume of contrast needed to fill the cavity, it provide an accurate gauge of size. Usually if more than 6cc of contrast is used before tubal filling is observed, the uterus is pathologically enlarged (26).

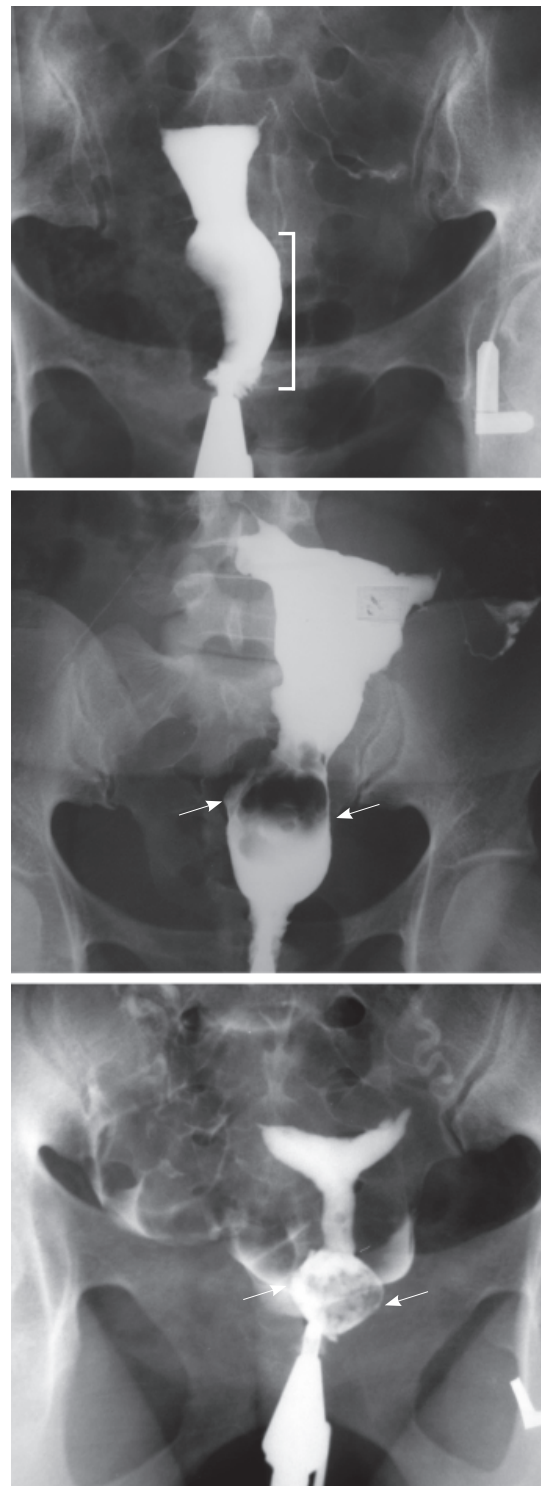


Fig 14: *Curved, elongation and distortion (arrows) of cervical canal by large leiomyoma in different cases.*

Uterine cavity enlargement is very reliable sign of the presence of a myoma, but it may not indicate its exact location (anterior, posterior, fundus, or body) unless there is an accompanying indentation of the

wall or a filling defect (Fig 20). Lateral or oblique views and correlation with ultrasound can further pinpoint the position of the myoma.

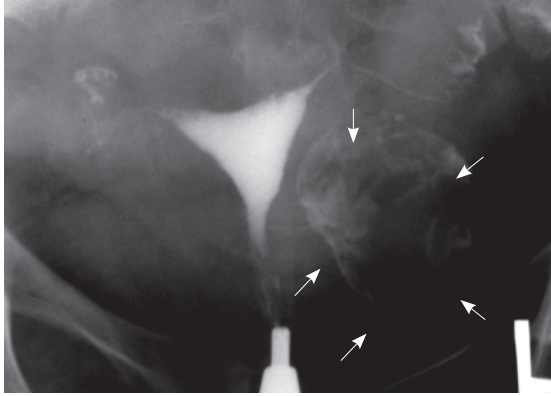


Fig 15: Large calcified subserosal myoma. The uterine cavity demonstrates normal triangular shape. The size of tumor is clearly indicated (arrows) and should be differentiated from the calcified ovary.

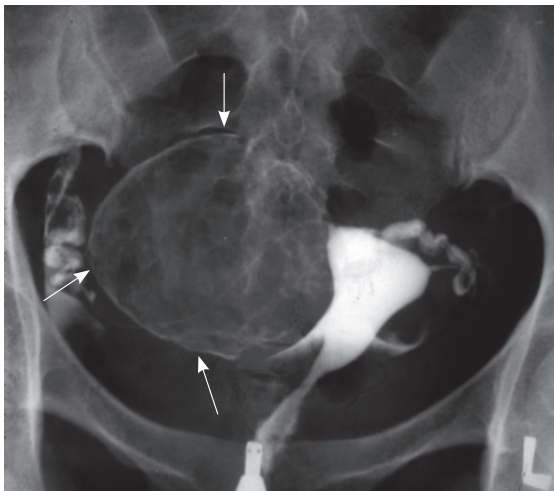


Fig 16: Large subserosal myoma in the right wall without pressure defect (arrows). The triangular shape of the cavity is preserved.

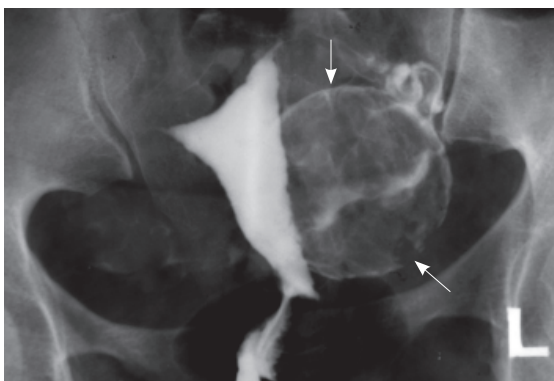


Fig 17: Large calcified and sharply outlined myoma elongating left border (arrows). This coarse calcified pattern is relatively typical for myoma.

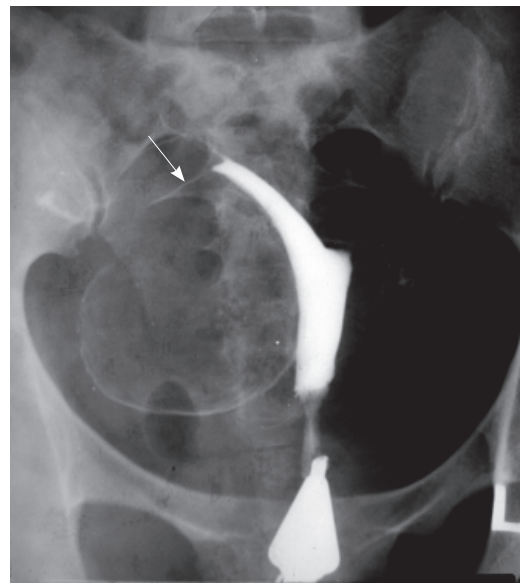


Fig 18: Large calcified myoma of the right uterine wall. Elongation and distortion of the cavity due to extensive pressure of the myoma on the right wall. The right tube is stretched over the surface of the tumor (arrow).

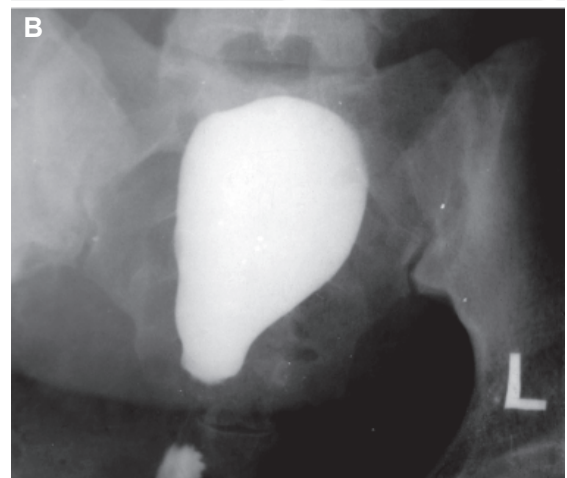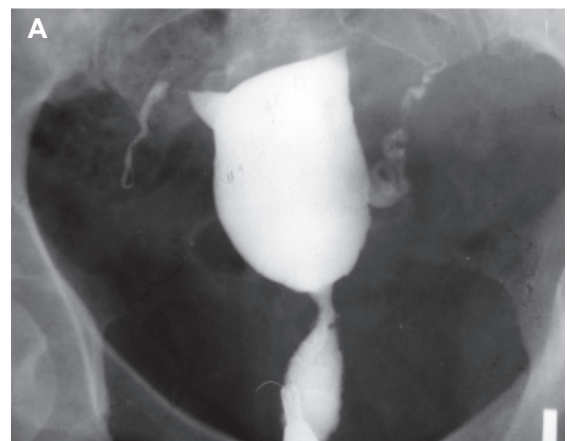


Fig 19: A, B. Generalized enlargement of the uterine cavity due to intramural myoma. The uterus is atonic and flabby. More than 15 ml of contrast medium filled the cavity.

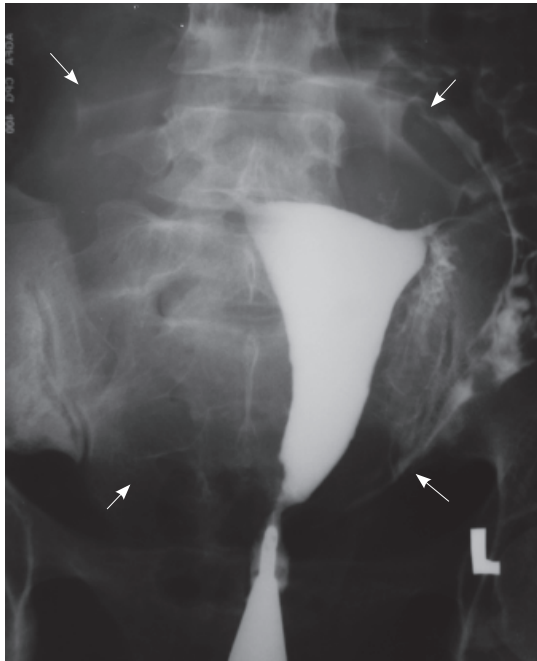


Fig 20: Generalized enlargement of the uterus due to myomato uterus (arrows). The exact location of the myoma is not indicated.

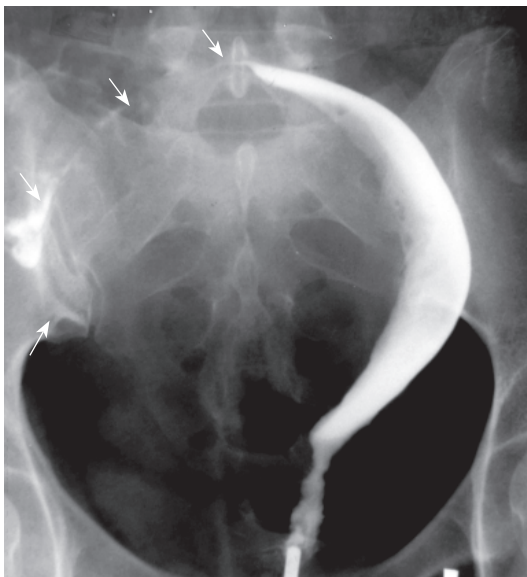


Fig 21: Markedly enlarge intramural leiomyoma of the right uterine wall. Elongation, distortion and compression of the uterine cavity giving the crescentic sign. The right tube is stretched over the surface of the tumor.

A uterine horn housing a small myoma becomes disproportionately larger than the contra lateral horn; therefore tubal occlusion may be resulted.

Asymmetric enlargement of the uterus produced by large intramural or subserosal myoma gives the uterus a Crescenting sign appearance (Fig 21).

Smooth and symmetric fundal myomas may simulate a subseptate or bicornuate uterus (Fig 22A, B).

Accurate localization is valuable to the surgeon who

wants keep uterine incisions to a minimum during myomectomy and has a special interest in removing the submucosal myomas responsible for most of the patient's symptoms. Hysteroscopic excision of small fibroids is an alternative to myomectomy (27). After myomectomy, hysterosalpingography reveals that even a greatly distorted uterine cavity can return to normal (28).

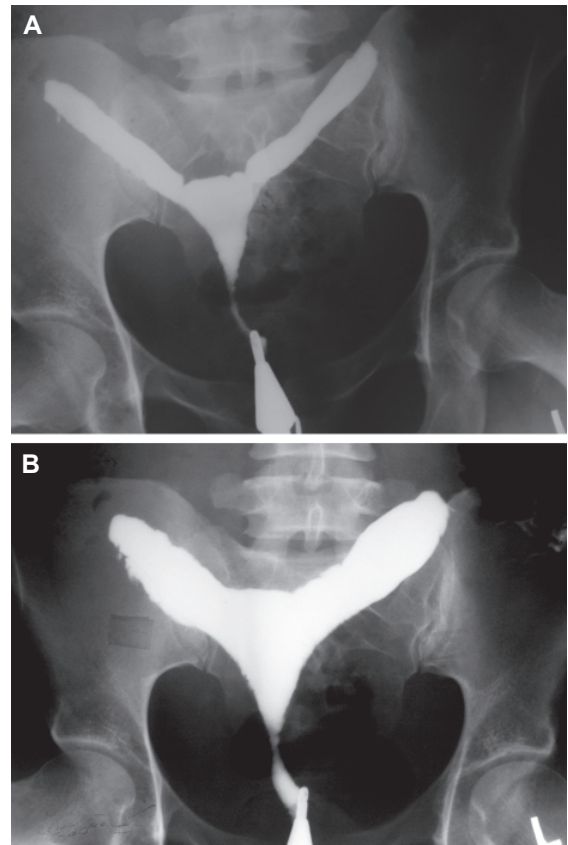


Fig 22: A, B. Early and late filling views of the hysterosalpingogram show an enlarged myoma located at the fundus. Increase in the distance between the cornua is seen. The uterus resembles a bicornuate uterus due to pressure defect of the tumor.

Conclusion

HSG is a reliable technique for diagnosis of intrauterine abnormalities. Although hysteroscopy is the gold standard in the detection of intrauterine pathology in patients with infertility; hysterosalpingography remains the most sensitive investigation in the evaluation of the lumen of the uterus and fallopian tubes, especially, in patients with primary or secondary infertility.

References

1. Cramer SF, Horiszny JA, Leppert P. Epidemiology of uterine leiomyomas. *J reprod Med*, 1995; 40: 595-600
2. Cramer SF, Patel A. The frequency of uterine leiomyomas. *Am J Clin Pathol*. 1990; 94(4): 435-438
3. Lurie S, Piper I, Woliovitich I, Glezerman M. Age-related

- prevalence of sonographically confirmed uterine myomas. *J Obstet Gynaecol.* 2005; 25(1): 42-44
4. Lethaby A, Vollenhoven B. Fibroids (uterine myomatosis, leiomyomas). *Am Fam Physician. Review,* 2005; 71(9): 1753-1756.
 5. Marshall LM, Spiegelman D, Barbieri RL, Goldman MB, Manson JE, Colditz GA, et al. Variation in the incidence of uterine leiomyoma among premenopausal women by age and race. *Obstet Gynecol.* 1997; 90(6): 967-973
 6. Roma Dalfó A, Ubeda B, Ubeda A, Monzón M, Rotger R, Ramos R, et al. Diagnostic value of hysterosalpingography in the detection of intrauterine abnormalities: a comparison with hysteroscopy. *AJR Am J Roentgenol.* 2004; 183(5): 1405-1409
 7. Barbot J. Hysteroscopy and hystero-graphy. *Obstet Gynecol Clin North Am. Review,* 1995; 22(3): 591-603
 8. Hashimoto K, Azuma C, Kamiura S, Kimura T, Nobunaga T, Kanai T, et al. Clonal determination of uterine leiomyomas by analyzing differential inactivation of the X-chromosome-linked phosphoglycerokinase gene. *Gynecol Obstet Invest.* 1995; 40(3): 204-208
 9. Townsend DE, Sparkes RS, Baluda MC, McClelland G. Unicellular histogenesis of uterine leiomyomas as determined by electrophoresis by glucose-6-phosphate dehydrogenase. *Am J Obstet Gynecol.* 1970; 107(8):1168-1173
 10. Ross RK, Pike MC, Vessey MP, Bull D, Yeates D, Casagrande JT. Risk factors for uterine fibroids: reduced risk associated with oral contraceptives. *Br Med J (Clin Res Ed).* 1986; 293(6543): 359-362
 11. Chiaffarino F, Parazzini F, La Vecchia C, Marsico S, Surace M, Ricci E. Use of oral contraceptives and uterine fibroids: results from a case-control study. *Br J Obstet Gynaecol.* 1999; 106(8): 857-860
 12. Kjerulff KH, Langenberg P, Seidman JD, Stolley PD, Guzinski GM. Uterine leiomyomas. Racial differences in severity, symptoms and age at diagnosis. *J Reprod Med.* 1996; 41 (7): 483-490
 13. Schwartz SM, Marshall LM, Baird DD. Epidemiologic contributions to understanding the etiology of uterine leiomyomata. *Environ Health Perspect.* 2000; 108 Suppl 5: 821-827
 14. Boynton-Jarrett R, Rich-Edwards J, Malspeis S, Missmer SA, Wright R. A prospective study of hypertension and risk of uterine leiomyomata. *Am J Epidemiol.* 2005 1; 161(7): 628-638
 15. Evans P, Brunzell S. Uterine fibroid tumors: diagnosis and treatment. *Am Fam Physician.* 2007; 75(10): 1503-1508
 16. Leiomyoma-related bleeding: a classic hypothesis updated for the molecular era. *Hum Reprod Update.* 1996; 2(4): 295-306
 17. Farhi J, Ashkenazi J, Feldberg D, Dicker D, Orvieto R, Ben Rafael Z. Effect of uterine leiomyomata on the results of in-vitro fertilization treatment. *Hum Reprod,* 1995; 10: 2576-2578
 18. Eldar-Geva T, Meagher S, Healy DL, Maclachlan V, Breheny S, Wood C. Effect of intramural, subserosal, and submucosal uterine fibroids on the outcome of assisted reproductive technology treatment. *Fertil Steril,* 1998; 70: 687-691
 19. Kessler A, Mitchell DG, Kuhlman K, Goldberg BB. Myoma vs. contraction in pregnancy: differentiation with color Doppler imaging. *J Clin Ultrasound.* 1993; 21(4): 241-244
 20. Vardi JR, Tovell HM. Leiomyosarcoma of the uterus: clinicopathologic study. *Obstet Gynecol.* 1980; 56(4): 428-434
 21. Van Dinh T, Woodruff JD. Leiomyosarcoma of the uterus. *Am J Obstet Gynecol.* 1982 1; 144(7): 817-823
 22. Berchuck A, Rubin SC, Hoskins WJ, Saigo PE, Pierce VK, Lewis JL Jr. Treatment of uterine leiomyosarcoma. *Obstet Gynecol.* 1988; 71(6 Pt 1): 845-850
 23. Krysiwicz S. Infertility in women: diagnostic evaluation with hysterosalpingography and other imaging techniques. *AJR Am J Roentgenol.* 1992; 159(2): 253-261
 24. Dudiak CM, Turner DA, Patel SK, Archie JT, Silver B, Norusis M. Uterine leiomyomas in the infertile patient: preoperative localization with MR imaging versus US and hysterosalpingography. *Radiology.* 1988; 167(3): 627-630
 25. Panageas E, Kier R, McCauley TR, McCarthy S. Submucosal uterine leiomyomas: diagnosis of prolapse into the cervix and vagina based on MR imaging. *AJR Am J Roentgenol.* 1992; 159(3): 555-558
 26. Pietilä K. Hystero-graphy in the diagnosis of uterine myoma. Roentgen findings in 829 cases compared with the operative findings. *Acta Obstet Gynecol Scand Suppl.* 1969
 27. DeCherney A, Polan ML. Hysteroscopic management of intrauterine lesions and intractable uterine bleeding. *Obstet Gynecol.* 1983; 61(3): 392-397
 28. Weinstein D, Aviad Y, Polishuk WZ. Hystero-graphy before and after myomectomy. *AJR Am J Roentgenol.* 1977; 129(5): 899-902