

Successful Treatment of Obstructive Oligospermia/Azoospermia Due to Mullerian Duct Cyst by Transurethral Resection: A Case Report

Ahmad Vosough, M.D.^{1*}, Faramarz Farahi, M.D.¹, Mohamad Ali Sadighi Gilani, M.D.¹,
Fatemeh Zafarani, B.Sc.², Firoozeh Ahmadi, M.D.²

1. Andrology Department, Royan Institute

2. Endocrinology and Female Infertility Department, Royan Institute

Abstract

Cystic lesions in midline of prostate are uncommon and considered as congenital disorders. Here we report a 33- year- old male who presented with either azoospermia or decreased ejaculate volume leading to infertility and for whom performing Transrectal ultrasonography had a critical role in diagnosis. The obtained images revealed a congenital cyst of the prostate gland just in middle portion of prostate. Transurethral resection (TUR) of the cyst subsequently resulted in normalization of the semen analysis and restitution of the patient's fertility. Spontaneous pregnancy occurred 2 months after TUR.

Transrectal ultrasonography currently is the most accurate, inexpensive and readily available noninvasive imaging technique used to diagnose obstruction of the ejaculatory ducts in the infertile patient with either azoospermia or low ejaculate volume.

Introduction

Ejaculatory duct obstruction (EDO) is an uncommon cause of obstructive azoospermia and occurs in 5- 8% of all cases of ductal obstruction. These patients usually present with low-volume oligospermia or azoospermia, haematospermia, normal physical examination and normal serum gonadotropin level (1-2).

Such obstruction may be congenital (enlarged midline utricular cyst, mullerian duct cyst) or acquired (after posterior urethral inflammation or prostatic infection) (3-7).

Müllerian duct cysts arise in the midline, either within the posterior aspect of the prostate or extending behind the prostate and bladder neck. Although they are commonly asymptomatic, these cysts can result in infertility due to ejaculatory duct obstruction⁸. It has been reported that medial prostatic cysts may be observed in 5% of outpatients with urologic symptoms (9-10). The incidence in apparently healthy men is, however, unknown (11).

Mullerian duct cysts may obstruct only one ejaculatory duct and thus the patient may refer to an infertility clinic with oligospermia and/or haematospermia.

These cysts can be diagnosed directly by vasography or indirectly by transrectal ultrasonography (TRUS). Due to non-invasive nature, TRUS is currently the diagnostic method of choice (12).

This article reports a patient presenting with infertility for whom transrectal ultrasonography was performed. A cyst of the prostatic utricle was detected and subsequently removed surgically which resulted in normalization of the semen analysis and restitution of the patient's fertility.

Case Report

A 33- year- old man, with a history of 12-year primary infertility, severe oligospermia/azoospermia (Seminal volume of 0.5 mL, pH of 6.8 and sperm density of 0.8×10^6 /mL), normal karyotype and with no history of familial infertility was referred to Royan Institute (Infertility Clinic & Reproductive Biomedicine Research Center). Physical examination was normal. Serum T, FSH and LH were normal. He underwent two cycles of ICSI¹ in our institute with unfortunately, no success. Semen analysis yielded azoospermia.



As part of investigation, transrectal ultrasonography (TRUS) of prostate and seminal vesicles was performed by Bi-plane transducer.

The diameter of prostate was measured 3.8×3.0×1.7cm and the paranchymal echogenesity was non-homogenous. There was an echo-free structure (cystic lesion of ejaculatory duct) measuring 2.1×1 cm lying just in middle portion of prostate. Both seminal vesicles were seen with non-homogenous echogenicity and cystic formation. Both vasodeferans were dilated (Figure 1-2).

Transurethral Resection of the Mullerian duct cyst was performed and histological examination was consistent with the diagnosis. Antibiotic therapy was applied pre- and postoperatively. One month after the operation semen analysis revealed a seminal volume of 3.5 mL, pH of 7.3 and sperm density of 19×10⁶/mL. Semen fructose test was mildly positive. Spontaneous pregnancy occurred 2 months after TUR.

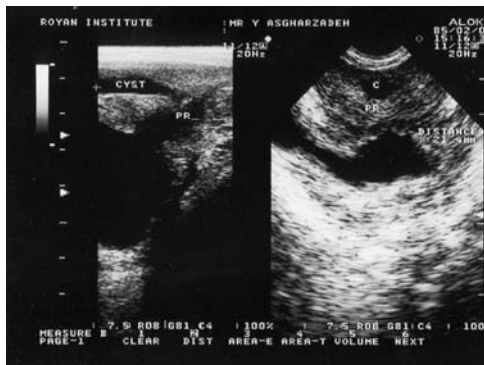


Figure1: Transrectal ultrasound scan of the cystic lesion in middle portion of prostate (Transverse image and longitudinal image)

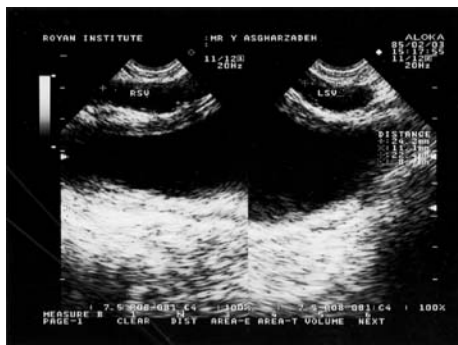

Figure 2: Transrectal ultrasound images of both seminal vesicles showing tortuous and cystic formation (Transverse image)

Discussion

Due to the success of assisted reproductive techniques (IVF/ICSI) and regardless of the etiology of male sub-fertility, appropriate evaluation is often bypassed, although several causes can be effectively treated. The widespread utilization of TRUS for diagnosis of low ejaculate volume, azoospermia or oligozoospermia in sub-fertile men has resulted in more frequent detection of midline prostatic cysts (13). Several treatments such as transurethral resection of the ejaculatory ducts (TURED), transrectal aspiration together with sclerotherapy, transurethral marsupialization and open surgery of the midline prostatic cyst have been described (14-20). Currently, in young males the standard treatment is TURED because of high success rate in preserving fertility and potency (15, 17-20).

We believe that transurethral resection of the cyst provides a safe treatment in selected cases. Authors recommend a more careful and detailed evaluation of oligo/azoospermic patients, in order to rule out treatable types of ejaculatory duct obstruction prior to decision upon intracytoplasmic sperm injection.

References

1. Hull MG, Glazener CM, Kelly NJ, Conway DI, Foster PA, Hinton RA, Coulson C, Lambert PA, Watt EM, Desai KM. Population study of causes, treatment, and outcome of infertility. *Br Med J (Clin Res Ed)*. 1985; 291(6510): 1693-1697
2. Turek PJ, Magana JO, Lipshultz LI. Semen parameters before and after transurethral surgery for ejaculatory duct obstruction. *J Urol*. 1996; 155(4): 1291-1293
3. Fisch H, Lambert SM, Goluboff ET. Management of ejaculatory duct obstruction: etiology, diagnosis, and treatment. *World J Urol*. 2006; 24(6): 604-610
4. Kumar R, Gautam G, Gupta NP, Aron M, Dada R, Kucheria K, Gupta SK, Mitra A. Role of testicular fine-needle aspiration cytology in infertile men with clinically obstructive azoospermia. *Natl Med J India*. 2006; 19(1): 18-20
5. Heshmat S, Lo KC. Evaluation and treatment of ejaculatory duct obstruction in infertile men. *Can J Urol*. 2006; 13Suppl, 1: 18-2
6. Johnson CW, Bingham JB, Goluboff ET, Fisch H. Transurethral resection of the ejaculatory ducts for treating ejaculatory symptoms. *BJU Int*. 2005; 95(1): 117-119
7. Halpern EJ, Hirsch IH. Sonographically guided transurethral laser incision of a Mullerian duct cyst for treatment of ejaculatory duct obstruction. *AJR Am J Roentgenol*. 2000; 175 (3): 777-778

8. Patterson L, Jarow JP. Transrectal ultrasonography in the evaluation of the infertile man: a report of 3 cases. *J Urol* 1990; 144: 1469-1471
 9. Jequier MA. Obstructive lesions of the male genital tract. In: *Male infertility*. 1st ed, Blackwell Science, Edinburgh, 2000; 181-103
 10. Dik P, Lock TM, Schrier BP, Zeijlemaker BY, Boon TA. Transurethral marsupialization of a medial prostatic cyst in patients with prostatitis-like symptoms. *J Urol*. 1996; 155(4): 1301-1304
 11. Ishikawa M, Okabe H, Oya T, Hirano M, Tanaka M, Ono M, Kawamura K, Fujimoto N, Sakurada K. Midline prostatic cysts in healthy men: incidence and transabdominal sonographic findings. *AJR Am J Roentgenol*. 2003; 181(6): 1669-1672
 12. Jarow JP. Transrectal ultrasonography of infertile men. *Fertil Steril*. 1993; 60(6): 1035-1039
 13. Kim ED, Onel E, Honing SC. The prevalence of cystic abnormalities of the prostate involving the ejaculatory ducts as detected by transrectal ultrasound. *Int. Urol. Nephrol*, 1997; 29, 647-652
 14. Ritchey ML, Benson RC Jr, Kramer SA, Kelalis PP. Management of mullerian duct remnants in the male patient. *J Urol*. 1988; 140(4): 795-799
 15. Fisch H. Transurethral resection of the ejaculatory ducts. *Curr Surg Tech Urol*, 1992; 5: 2-7
 16. Stricker HJ, Kunin JR, Faerber GJ. Congenital prostatic cyst causing ejaculatory duct obstruction: management by transrectal cyst aspiration. *J Urol*. 1993; 149(5):1141-1143
 17. Jarow JP. Diagnosis and management of ejaculatory duct obstruction. *Techniques in Urology*, 1996; 2: 79-85
 18. Mecham RB, Hellerstein DK, Lipshultz, LI. Evaluation and treatment of ejaculatory duct obstruction in the infertile male. *Fertil Steril* 1993; 59: 393-397
 19. Yildirim I, Kibar Y, Sumer F, Bedir S, Deveci S, Peker AF. Intraurethral prostatic cyst: a rare cause of infravesical obstruction. *Int Urol Nephrol*. 2003; 35(3): 355-356
 20. Hendry WF, Pryor JP. Müllerian duct (Prostatic utricle) cyst: Diagnosis and treatment in sub-fertile males. *Br J of Urol*, 1992; 69, 79-82
-