

## Case Report

# Coincidence of Cystic Fibrosis in Mother and her Child Related to Infertility

Mehri Najafi Sani, M.D.<sup>1</sup>, Armen Malekiyan, M.D.<sup>1</sup>, Alireza Nikzad Jamnani, M.D.<sup>2\*</sup>

1. Children Medical Center Hospital, Tehran University School of Medical Sciences, Tehran, Iran

2. Children's Hospital, Tabriz University of Medical Sciences, Tabriz, Iran

### Abstract

Cystic fibrosis (CF), the most common life-shortening, hereditary disease in whites, manifests itself principally in childhood. Patients presenting with CF as adults appear to be different when compared to patients diagnosed with CF during childhood. Often these patients have been previously diagnosed with asthma, chronic bronchitis or emphysema.

We present a case of a woman diagnosed with CF at age 37 years. We noticed her finger clubbing during her son's hospital admission for CF decompensation. Taking a thorough history, she complained of chronic productive cough and was treated for hyper reactive airway disease for many years. A Computed Tomography scan was performed which showed bronchiectasis, atelectasis and the presence of a honey comb pattern in her lung fields. Two sweat tests were performed, both of which were strongly positive. Her CF diagnosis was confirmed.

The clinical course of patients receiving a diagnosis of CF in adulthood is largely unknown, but frequently they have milder disease and a more favorable prognosis. The proportion and number of patients with CF diagnosed in adulthood has increased. A large number of these patients present with subtle symptoms or single-organ disease. Since the majority have pulmonary disease CF should be included in the differential diagnosis of chronic respiratory symptoms in adults.

**Keywords:** Cystic Fibrosis, Clubbing, Infertility, Pregnancy

### Introduction

Cystic fibrosis (CF), the most common life-shortening, hereditary disease in whites, is described as a disease that manifests itself principally in childhood. It is documented that patients presenting with CF in adulthood appear to be different when compared to patients presenting in childhood. They tend to have more subtle findings and traditional sweat test results may not be positive (1).

Clinical features that lead to the diagnosis include respiratory symptoms and chronic airway infection with typical CF pathogens such as *Pseudomonas aeruginosa*, *Staphylococcus aureus* as well as nontuberculous mycobacteria. Often these patients have formerly received a diagnosis of either asthma, chronic bronchitis, or emphysema. Pancreatic insufficiency is much less common in adults diagnosed with CF, but pancreatitis occurs with greater frequency. Although lung disease is generally less severe in CF patients diagnosed as adults than in adult patients who have been diagnosed as infants, the extent of bronchiectasis can nonetheless be severe (2, 3).

CF is a genetic recessive disorder caused by muta-

tions in the gene that encodes the CFTR protein. The diagnosis of CF in adults should be based on the presence of one or more characteristic clinical features, a history of CF in a sibling; plus evidence of defective CFTR function, as documented by elevated sweat chloride concentrations or abnormal ion transport across the nasal epithelium, or identification of mutations on both CFTR genes (4).

### Case Report

We present the case of a woman diagnosed with CF at age 37 years. An 8 year-old male, who was a known to have CF, [confirming positive sweat test (Na=60 mEq/L, Cl=75 mEq/L, volume: 120)], since early infancy taking Creon capsules and vitamin supplements] was admitted to our hospital. During his admission, due to respiratory decompensation, we noticed his mother's fingers were clubbed. She was a 37 year old lady in no apparent distress. Taking a thorough history, she complained of chronic productive cough and was treated for hyper reactive airway disease for many years. While taking drugs for her presumed

Received: 17 Feb 2010, Accepted: 10 Apr 2010

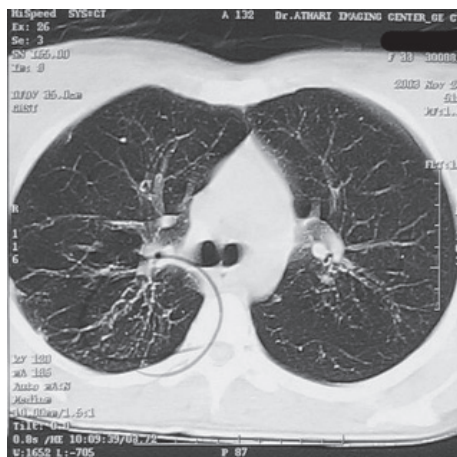
\* Corresponding Address: P.O.Box: 4765935973, Children's Hospital, Tabriz University of Medical Sciences, Tabriz, Iran  
Email: alirezanikzad@yahoo.com



Royan Institute  
International Journal of Fertility and Sterility  
Vol 4, No 2, Jul-Sep 2010, Pages: 85-87

hyper reactive airway disease; she was never free of symptoms. Her childhood history was not significant except for recurrent respiratory infections which were managed in an outpatient setting. She was never hospitalized for her condition and had no history of malabsorption. This lady has a greater than 12 year history of infertility and her child, who has CF, was born as the result of in vitro fertilization (IVF). During the infertility workup no reason was given for her infertility and it was suggested that the couple undergo IVF.

On physical examination her chest diameter was slightly increased. During auscultation we noticed crackles and localized wheezing. Her abdomen was normal. Her extremities were prominent for clubbing. A chest radiograph was taken due to her respiratory complaints which indicated air trapping and peribronchial thickening. A CT scan was performed which showed bronchiectasis, atelectasis, and a honey comb pattern in her lung fields (Fig 1).



**Fig 1: Computed Tomography which demonstrates bronchiectasis, atelectasis, and a honey comb pattern in her lung fields.**

According to her long term symptoms that did not respond to conventional asthma treatments, her child's known diagnosis of CF and radiographic findings, a sweat test was done. Her sweat test was positive (Na=130 mEq/L, Cl=128 mEq/L, volume: 620 ml). A second sweat test was performed which was also positive (Na=118 mEq/L, Cl=110 mEq/L, volume: 590 ml). Her blood chemistry panel was normal. To assess her pancreatic function, a stool exam was performed which showed a formed brown stool that was negative for fat and contained undigested food. On Sudan staining no fat droplets were seen. Trypsin enzyme activity was 1/48 which is in favor of a slight decrease in trypsin activity. When we informed her about the

diagnosis, she refused further diagnostic or therapeutic workup. Two weeks later her child was discharged after the necessary treatments. In a clinic follow up two months later the child was doing well, however the mother had still chronic cough which now interrupted her daily activities. At last she accepted to be referred to an adult clinic for further workup and treatment.

## Discussion

CF is the most common lethal inherited disease in the caucasian population, with an autosomal recessive pattern that presents in children of carrier parents. Its incidence depends on race and varies between different populations (from 1 / 2500–1 / 9000). Of note, CF is not more common in children whose mothers are diagnosed; as concluded by Cohen LF, whose research is published in *Lancet* (5). In a survey of 119 CF centers in the U.S.A. and Canada, Cohen obtained information on 129 pregnancies in 100 patients with CF. There were 97 pregnancies completed which resulted in 86 viable infants, only one of whom had CF. This is close to the expected incidence and attests to the recessive nature of the transmission of CF (5).

Barak et al. conducted a study on pregnant women with a known diagnosis of CF. 27 year analysis of the National CF Registry found 8 CF women with 11 pregnancies who delivered 12 neonates. None of the neonates had CF (6).

Because of fertility problems in the CF female, significant risk for pregnant CF women, and a high rate of prenatal death; these women have a lower chance to have a baby in proportion to the normal population.

After birth, vomiting and not passing stool occurs in 10-15% of CF patients (7). The most common presentation in childhood is failure to thrive because of exocrine pancreatic insufficiency, often in combination with chronic cough (8). When the diagnosis is missed in early childhood, disease complications may occur and eventually lead to the diagnosis: clubbing, bronchiectasis, chronic sinusitis, nasal polyps, liver cirrhosis, hematemesis, hemoptysis, etc (9). The clinical course of patients receiving a diagnosis of CF in adulthood is largely unknown, but frequently they have milder disease and a more favorable prognosis (2, 3).

As we stated, pancreatic insufficiency is the main cause of failure to thrive in CF patients but some genotypes are associated with better preservation of pancreatic function. These patients are more prone to episodes of acute pancreatitis during adolescence and adulthood (10). Our patient had no history of malabsorption and her stool exam was

negative for fat. As an adult diagnosed with CF, it was predictable not to have pancreatic insufficiency but she also had no episode of pancreatitis, which is more common in this age group.

Women with CF have diminished fertility and pregnancy may be a threat to their health, especially when they have compromised lung function (11). Our patient was a case of 12 years infertility before giving birth to her CF child; her unexplained infertility could have been a clue for an earlier diagnosis of CF but it remained unnoticed?.

The sweat test remains the hallmark diagnostic test for CF (12). The quantitative pilocarpine iontophoresis sweat test developed by Gibson and Cooke remains the test of choice (13). An accurately performed sweat test has a high diagnostic yield. A sweat chloride concentration of > 60 mEq/L confirms the diagnosis of CF in patients with suggestive clinical symptoms (9). We recommend repeated sweat tests when borderline values are obtained. If there is a strong clinical suspicion of CF, normal or intermediate values do not exclude a diagnosis of CF, especially in older people (14). It is documented that adult patients diagnosed with CF most probably have equivocal sweat test results, but our patient's test result is strongly positive.

The proportion and number of patients with CF diagnosed in adulthood have increased. A large number of these patients present with subtle symptoms or single-organ disease. The majority have pulmonary disease. CF can affect multiple organs, and there is a potential for future complications, which could be anticipated or treated earlier with a confirmed diagnosis. Patients with CF diagnosed as adults should be informed that they are different from patients diagnosed in childhood. (1). Clinicians must be aware of the potential for adults with chronic respiratory tract infections, unexplained bronchiectasis, congenital bilateral absence of the vas deferens, or pancreatitis to have CF despite the age at presentation (2, 3).

### Conclusion

CF should be included into the differential diagnosis of chronic respiratory symptoms in adults. CF patients diagnosed in adulthood usually have a

milder clinical course of the disease.

---

### References

1. Gilljam M, Ellis L, Corey M, Zielenski J, Durie P, Tullis DE. Clinical Manifestations of Cystic Fibrosis Among Patients With Diagnosis in Adulthood. *Chest*. 2004; 126: 1215-1224.
  2. Nick JA, Rodman DM. Manifestations of cystic fibrosis diagnosed in adulthood. *Curr Opin Pulm Med*. 2005 Nov; 11(6): 513-518.
  3. de Gracia J, Alvarez A, Mata F, Guarner L, Vendrell M, Gadtner S, et al. Cystic fibrosis in adults: study of 111 patients. *Med Clin (Barc)*. 2002; 119(16): 605-609.
  4. Chinet T, Fajac I, Ferec C, Garcia Carmona T, Nguyen-Khoa T. Diagnosis of cystic fibrosis in adults. *Rev Mal Respir*. 2000; 17(3 Pt 2):739-748.
  5. Cohen LF, di Sant'Agnese PA, Friedlander J. Cystic fibrosis and pregnancy, A national survey. *Lancet*. 1980; 2(8199): 842-844.
  6. Barak A, Dulitzki M, Efrati O, Augarten A, Szeinberg A, Reichert N, et al. Pregnancies in women with cystic fibrosis. *Isr Med Assoc J*. 2005; 7(2): 95-98.
  7. Mushtaq I, Wright VM, Drake DP, Meams MB, Wood CB. Meconium ileus secondary to cystic fibrosis. The East London experience. *Pediatr Surg Int*. 1998; 13: 365-369.
  8. Lai HJ, Cheng Y, Farrel PM. The survival advantage of patients with cystic fibrosis diagnosed through neonatal screening: evidence from the United States Cystic Fibrosis Foundation registry data. *J Pediatr*. 2005; 147: 57-63.
  9. De Boeck K. Diagnostic procedures, clinical characteristics and counseling in cystic fibrosis. *Ann Nestle [Engl]*. 2006; 64: 119-129.
  10. De Boeck K, Weren M, Proesmans M, Kerem E. Pancreatitis among patients with cystic fibrosis: correlation with pancreatic status and genotype. *Pediatrics*. 2005; 115: 463-469.
  11. Edenborough FP, Stableforth DE, Webb AK, Mackenzie WE, Smith DL. Outcome of pregnancy in women with cystic fibrosis. *Thorax*. 1995; 50: 170-174.
  12. LeGrys, V Assessment of sweat-testing practices for the diagnosis of cystic fibrosis. *Arch Pathol Lab Med*. 2001; 125, 1420-1424.
  13. Gibson LE, Cooke RE. A test for concentration of electrolytes in sweat in cystic fibrosis of the pancreas utilizing pilocarpine by iontophoresis. *Pediatrics*. 1959; 23: 545-549.
  14. Stewart B, Zabner J, Shuber A, Welsh MJ, McCray PB Jr. Normal sweat chloride values do not exclude the diagnosis of cystic fibrosis. *Am J Respir Crit Care Med*. 1995; 151: 899-903.
-