

Case Report

Retained Fetal Bone in Infertile Patients: Two Case Reports

Firoozeh Ghaffari, M.D.^{1*}, Ensieh Shahrokh Tehraninejad, M.D.^{1,2}, Kiandokht Kiani, M.Sc.¹

1. Endocrinology and Female Infertility Department, Royan Institute for Reproductive Biomedicine, ACECR, Tehran, Iran

2. Faculty of Medicine, Tehran University of Medical Sciences, Tehran, Iran

Abstract

The prolonged retention of fetal bone structure is an uncommon condition after a previous abortion. We describe two cases with fetal bone fragment amongst 3589 hysteroscopies (0.05%), who had no complaint other than secondary infertility. In both patients, hyperechogenic areas were found through transvaginal ultrasound and the bones were removed by hysteroscopy. Despite meticulous evaluation during hysteroscopy, some bones were not observed and were stable during the next sonography. According to the formation of fetal bones after 11 weeks of pregnancy; patients with secondary infertility who have a history of abortion that progressed beyond this time and endometrial hyperechoic areas by transvaginal ultrasound should be evaluated for any retained fetal bone. Hysteroscopy should be performed under abdominal ultrasonography guide to ensure fetal bone tissue is entirely removed during a single surgery.

Keywords: Bone, Infertility, Hysteroscopy, Endometrium, Ultrasonography

Introduction

The presence of fetal bone structure in the uterine cavity is a rare condition (1, 2). There have been some case reports of secondary infertility due to retained fetal bone fragments (2-4) however the exact incidence is unclear.

In a recent case report, the incidence of fetal bone present in diagnostic hysteroscopy was 0.15% (2). We present two cases of retained fetal bone fragments in 3589 hysteroscopies (0.05%) which were performed in 77930 (0.002%) infertile patients. The cases had only secondary infertility and their characteristics have been described in this case report study.

Case Report

Case 1:

A 33 year old woman G₁P0A₁ presented to our clinic with a 15 year history of secondary infertility. She had a history of one miscarriage at 16 weeks gestation. For all patients referred to our clinic a vaginal sonography is performed and after observing any abnormalities, they will be introduced for hysteroscopy. In this case transvaginal ultrasound revealed a hyperechogenic area in the endometrial cavity (Fig 1) and hysterosalpingography showed some linear filling defect in the uterine cavity. Hysteroscopy revealed several fetal bony fragments. The bones were removed with hysteroscopy by us-

ing grasper forceps. In histopathological examination bony trabeculae were seen.

A repeat ultrasound was done post operatively which showed echogenic areas in the endometrium all measuring approximately 8 mm. The second hysteroscopy was performed and showed a normal cavity and endometrium. A decision was made to proceed with *in vitro* fertilization (IVF). She was treated with the standard long protocol and embryo transfer (ET) freezing cycle. As mentioned before, she did not conceive with both the long protocol and ET freezing.

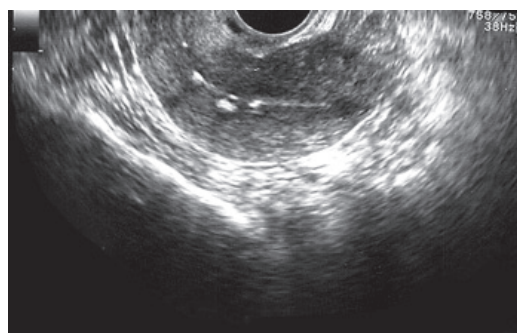


Fig 1: Hyperechogenic area in the endometrial cavity (Case 1).

Case 2:

A 31 year old female G₁P0A₁ was referred to our clinic with a history of secondary infertility. She had one induced abortion at 17 weeks due to anen-

Received: 23 Jun 2009, Accepted: 1 Sep 2009

* Corresponding Address: P.O.Box: 19395-4644, Endocrinology and Female Infertility Department, Royan Institute for Reproductive Biomedicine, ACECR, Tehran, Iran
Email: f.ghaffari@royaninstitute.org



Royan Institute
International Journal of Fertility and Sterility
Vol 3, No 3, Nov-Dec 2009, Pages: 153-154

cephalia two years ago. A routine pelvic ultrasound revealed some echogenic endometrial interfaces with posterior shadows (Fig 2) and hysteroscopy revealed several fetal bony fragments which were then removed by hysteroscopy. A repeat ultrasonography was done post operatively which showed an echogenic area in the endometrium which was suspicious for the presence of retained fetal bones. A second hysteroscopy to remove the remaining bones has not been performed yet.

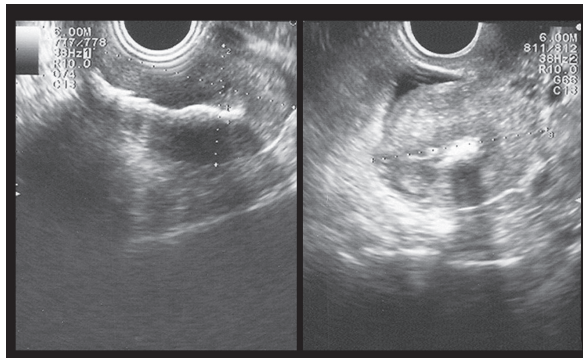


Fig 2: Some echogenic endometrial interfaces with posterior shadows (Case 2).

Discussion

Over the past decades there have been some case reports describing endometrial calcification due to retained fetal bone fragments. Another possibility is metaplasia of mature endometrial stromal cells because of chronic inflammation or trauma (5).

There are some articles reporting fetal bony fragments as a cause of secondary infertility (3, 4).

The diagnosis of retained fetal bone can be made by visualizing an endometrial hyperechogenic area on ultrasonography, identifying a filling defect in the hysterosalpingogram or a gritty feel to the endometrium during dilatation and curettage. Usually these fragments can be directly visualized by hysteroscopy and removed easily but sometimes bony fragments are held within the uterine cavity, embedded deep into the myometrium. Normal endometrium overgrows the deeply embedded fragments, so at hysteroscopy these fragments are overlooked and easily left (3).

Elford and Claman suggested using dilatation and

curettage along with an abdominal ultrasonography guide to ensure removal of all bony tissues (3). However, in the present case report we did not perform hysteroscopy along with an ultrasonographic guide, so some bony fragments were left. Because some bony fragments were embedded beneath the endometrium they could not be seen with a hysteroscope.

This study, for the first time, gives the incidence of retained fetal bone in a group of infertile patients (0.05%) in all hysteroscopies performed and in all infertile women (0.002%).

These case reports stress the need to perform ultrasonography after dilatation and curettage for all women who undergo therapeutic abortions beyond fetal bone formation to ensure that no fetal tissue is left. In the case of an endometrial hyperechogenic area in secondary infertility, hysteroscopy should be performed under abdominal ultrasonography guide to ensure that it can be entirely removed during a single surgery.

Acknowledgements

The authors gratefully thank all the couples who participated in the study and the co-workers of the Royan Institute of Infertility and Reproductive Health (especially Miss Fatemeh Hosseini), that without their contributions this work would not have been possible.

References

1. Tulandi T, Al-Sunaidi M, Arseneau J, Tonin PN, Arcand SL. Calcified tissue of fetal in utero. *Fertil Steril.* 2008; 89: 217-218.
2. Makris N, Stefanidis K, Loutradis D, Anastasiadou K, Hatjipappas G, Anstaklis A. The incidence of retained fetal bone revealed in 2000 diagnostic hysteroscopies. *JSLs.* 2006; 10 (1): 76-77
3. Elford K, Claman P. Novel treatment of a patient with secondary infertility due to retained fetal bone. *Fertil Steril.* 2003; 79: 1028-1030.
4. Kramer HM, Rhemrev JP. Secondary infertility caused by the retention of fetal bones after an abortion: a case report. *J Med Case Reports.* 2008; 2: 208.
5. Roth E, Taylor HB. Heterotopic cartilage in the uterus. *Obstet Gynecol.* 1966; 27: 838-844.