

Case Report

Holoprosencephaly: A Case Report and Review of Prenatal Sonographic Findings

Maryam Niknejadi M.D.*, Firoozeh Ahmadi M.D., Shohreh Irani, B.Sc.

Reproductive Imaging Division, Endocrinology and Female Infertility Department,
Reproductive Medicine Research Center, Royan Institute, ACECR, Tehran, Iran

Abstract

Holoprosencephaly is a rare intracranial abnormality. The incidence of holoprosencephaly is between 0.56-0.63 of 10,000 live-born infants¹⁰. It has classified into three degrees, alobar, semilobar and lobar. In this case report we are introducing a case of Holoprosencephaly, in 13 weeks of pregnancy which was twin. We could identified this abnormality and the reduction was done in the appropriate time. The role of prenatal sonography in recognition of the malformation and prognostic value of these features are discussed.

Keywords: Holoprosencephaly, Prenatal Diagnosis, Ultrasonographic Screening

Introduction

Holoprosencephaly is a rare intracranial abnormality arising from failure of the prosencephalon to cleave during early embryonic life, which results in different degrees of lateral ventricular fusion and facial defects (1). This condition is classified according to brain structures into lobar, semilobar and alobar, the latter being the most severe form (1). The most prominent sonographic features include the detection of a monoventricular cavity and fused thalami, with or without associated facial defects (2, 3). After 11 weeks gestation, a particularly important feature of this condition is dysmorphism of the choroids plexuses. In fetuses without

abnormalities, a cross-sectional view of these structures displays a characteristic "butterfly" like shape, whereas in fetuses with holoprosencephaly, the choroid plexuses are severely distorted or absent (4) in contrast, before 11 weeks gestation, the limitations of current image resolution obtained by transvaginal sonography may make the diagnosis of holoprosencephaly difficult. Indeed, care should be taken not to confuse holoprosencephaly with the normal appearance of the cerebral vesicles at this early gestational age, particularly the mesencephalon, which are prominent at about 9 weeks (1) (Fig 1).

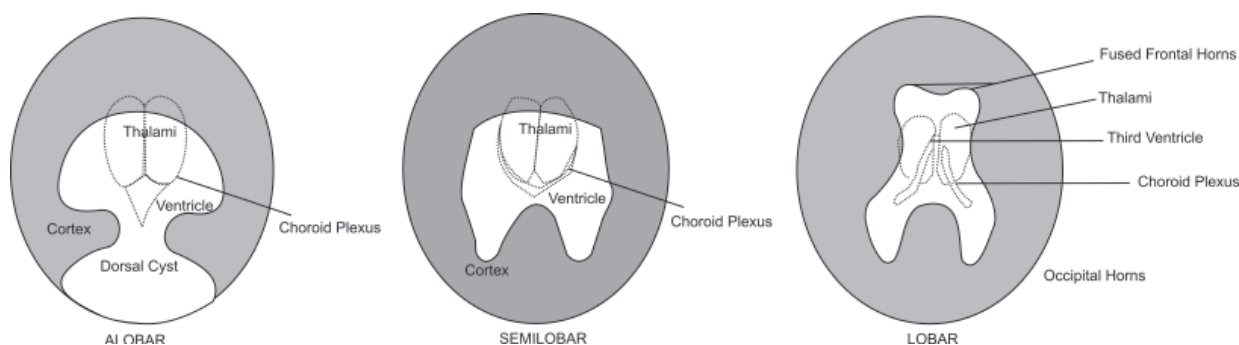


Fig 1: Types of holoprosencephaly

Received: 21 Aug 2008, Accepted: 29 Sep 2008

* Corresponding Address: P.O.Box: 19395-4644, Reproductive Imaging Division, Endocrinology and Female Infertility Department, Reproductive Medicine Research Center, Royan Institute, ACECR, Tehran, Iran

Email: m.niknejadi@royaninstitute.org



Royan Institute
International Journal of Fertility and Sterility
Vol 2, No 1, May-Jun 2008, Pages: 39-42

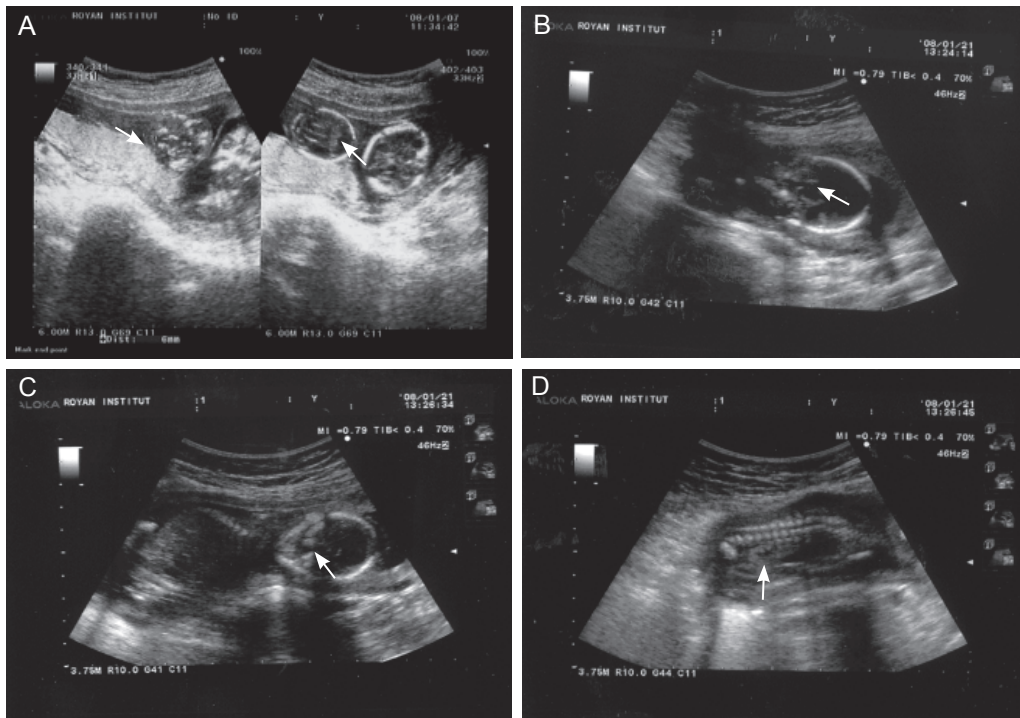


Fig 2: A: Two BPD that one of them shows thickened nuchal fold and holoprosencephaly. B: Alobar holoprosencephaly (monovertricle and fused thalmi) C: Midline facial defect. D: Enlarged echogenic kidneys

Case Report

A 34 year old pregnant woman with primary infertility, normal karyotype and no history of familial genetic disorders was admitted to Royan institute (infertility clinic & reproductive biomedicine research center). Her husband had a normal karyotype and the result of semen analysis was: Motility: %40 normal morphology: %10-%15, other items were normal. After work up she underwent the intra cytoplasmic sperm injection (ICSI) cycle with conventional protocol (GNRH/HMG).

BHCG was positive after 12 days of embryo transfer. In first ultrasonographic exam at 7 week, two gestational sac with two alive fetuses were seen. Sonographic evaluation at 15 week confirmed one of the fetuses 13 week and 5 days and the second one 15 week. This sonography determined the retard of growth in first fetus also shows the fused thalami and monovertricle in the center of the brain. At 17 week the holoprosencephaly was detected clearly also midline facial defect in face was seen. The both kidneys were larger than normal with echogenic pattern. The second one was normal. After prenatal consultation with parents they decided to do reduction at 17 weeks of pregnancy (Fig 2).

Discussion

Holoprosencephaly is a complex developmental

abnormality of the brain resulting from failure of cleavage of the primitive prosencephalon or forebrain Besides (5-8). common associated facial abnormalities include cyclopia, cebocephaly, ethmocephaly, median cleft lip (Fig 3).

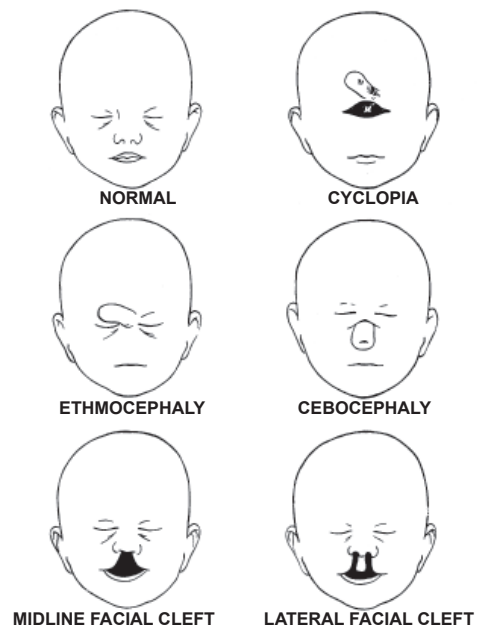


Fig 3: Different malformations seen with holoprosencephaly

According to the medical literature (5-8), there are three major varieties of holoprosencephaly, namely alobar, semilobar, and lobar. Alobar holoprosencephaly has been further subcategorized into three different configurations: the pancake, cup, and ball variation (5-8). In the alobar type as in our case the interhemispheric fissure and the falx cerebri are totally absent. In addition, there is a single primitive ventricle with fused thalami on the midline, associated with the absence of third ventricle, neurohypophysis, olfactory bulbs and tracts (5-8). In the semilobar variety, the cerebral hemispheres are partially separated posteriorly. Also, there is still a single ventricular cavity. As for lobar holoprosencephaly, the derangement of the brain is subtle. The cerebral hemispheres are completely divided with variable degrees of fusion of the lateral ventricle at the level of cingulate gyrus and frontal horns. The septum pellucidum is always absent and the olfactory bulbs and tracts as well as the corpus callosum may be absent, hypoplastic or completely normal (5-8) (Fig 4). Holoprosencephaly is one of the most frequently occurring abnormalities in aborted embryos and fetuses, occurring in about 4 of 1,000 induced abortions (9). The incidence of holoprosencephaly is between 0.56-0.63 of 10,000 live-born infants (10). They are often associated with chromosome abnormalities, mainly trisomy 13, trisomy 18, and triploidy (11). Early detection of holoprosencephaly, even in fetuses with normal karyotype, is very important because of its almost lethal outcome and major neurodevelopmental delay in surviving cases. The evaluation of the fetal brain must include a "butterfly sign" (4). In brief, a cross-sectional view of the fetal brain, in which two paired echogenic structures filling most of the ventricles (corresponding to the normal choroids plexus), with a characteristic appearance resembling a butterfly, should exist in normal fetuses (4). The teratogenic or genetic stimulus leading to holoprosencephaly is temporally located around the fourth week of gestation (12). The time frame of holoprosencephaly development is estimated to occur between weeks 4 and 6 of gestation (10). The most severe facial abnormalities were not always associated with alobar variant, as it was believed; so based on this evidence, probably the idea that "the face predicts the brain" (DeMyer, 1971) should be reformulated (13). Without chromosomal abnormalities, the recurrence risk of holoprosencephaly is estimated to be around 6%, including truly sporadic events and hereditary cases (14). Early diagnosis and termination of pregnancy may be suggested due

to its poor outcome. Although it is usually sporadic, genetic counseling and careful prenatal examination are warranted.

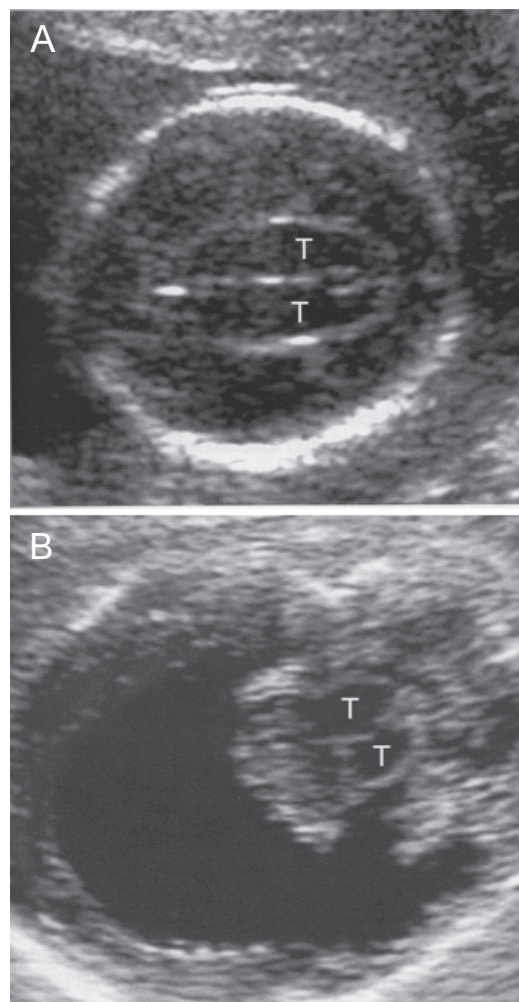


Fig 4: A and B, alobar type showing lack of the midline division of the brain anteriorly, prominence of the fused thalami (T) and crescent-shaped frontal cortex

References

1. McGahan JP, Pulu G, Nyberg DA. Cerebral malformations in: Nyberg DA, McGahan JP, Pretorius DH, Pulu G (eds). *Diagnostic imaging of fetal anomalies*. Philadelphia, PA: Lippincott Williams & Wilkins; 2003; 221-290.
2. Nelson LH, King M. Early diagnosis of holoprosencephaly. *J Ultrasound Med*. 1992; 11: 57-59.
3. Hsu TY, Chang SY, Ou CY, Chen ZH, Tsai WH, Chang MS, et al. First-trimester diagnosis of holoprosencephaly and cyclopia with triploidy by transvaginal three-dimensional ultrasonography. *Eur J Obstet Gynecol Reprod Biol*. 2001; 96: 235-237.
4. Supelveda W, Be C, Dezerrega V. First-trimester sonographic diagnosis of holoprosencephaly: value of the "butterfly" sign. *J Ultrasound Med*. 2004; 23: 761-765.
5. Cohen MM Jr. Perspectives on holoprosencephaly.

- part I. Epidemiology, genetics, and syndromology. *Teratology*. 1989; 40: 211-235.
6. Cohen MM Jr. Perspectives on holoprosencephaly. part III. Spectra, distinctions, continuities, and discontinuities. *Am J Med. Genet.* 1989; 34: 271-288.
7. Cohen MM Jr. Holoprosencephaly and cytogenetic findings: further information. *Am J Med Genet.* 1989; 34: 265.
8. DeMyer W. holoprosencephaly. In: Vinken PJ, Bruyn GW, eds. *Handbook of Clinical Neurology*. Amsterdam: Elsevier; 1977; 30: 431.
9. Matsunaga E, Shiota K. Holoprosencephaly in human embryos: epidemiologic studies of 150 cases. *Teratology*. 1977; 16(3): 261-272
10. Roach E, DeMyer W, Palmer K, Connelly M, Merritt A. Holoprosencephaly: birth data, genetic and demographic analysis of 30 families. *Birth Defect*. 1975; 11: 294-313.
11. Peeble DM. holoprosencephaly. *Prenat Diagn*. 1998; 18: 477-480.
12. Muller F, O'Rahilly R: Mediobasal prosencephalic defects, including holoprosencephaly and cyclopia, in relation to the development of the human forebrain. *Am J Anat*. 1989; 185: 391-414.
13. Sanz-Cortes M, Raga F, Bonilla-Musoles F. 3D sonographic prenatal diagnosis of lobar holoprosencephaly associated with cebocephaly. Assessment and diagnosis with multiplanar reconstruction. *Prenat Diagn*. 2007; 27(6): 585-586.
14. Odent S, Le Marec B, Munnich A, Le Merrer M, Boniti-Pellie C. Segregation analysis in nonsyndromic holoprosencephaly. *Am J Med Genet*. 1998; 77: 139-143.
-