

Assessing The Role and Accuracy of Ultrasonographic Imaging in The Diagnosis of Deep Infiltrating Endometriosis: A Cross-Sectional Study

Zahra Asgari, M.D.¹, Sara Farzadi, M.D.^{1,2*}, Reihaneh Hosseini, M.D.¹, Alireza Hadizadeh, M.D.³, Masoud Mortezaazadeh, M.D.⁴

1. Department of Obstetrics and Gynecology, Arash Women Hospital, Tehran University of Medical Sciences, Tehran, Iran

2. Reproductive Health Research Center, Department of Obstetrics and Gynecology, Al-Zahra Hospital, School of Medicine, Guilan University of Medical Sciences, Rasht, Iran

3. School of Medicine, Tehran University of Medical Sciences, Tehran, Iran

4. Internal Medicine Department, Sina Hospital, Tehran University of Medical Sciences, Tehran, Iran

Abstract

Background: Deep infiltrating endometriosis (DIE) is described as an endometriotic tissue that penetrates more than 5 mm under the peritoneal surface. It's suggested that trans vaginal sonography (TVS) is 79% sensitive and 94% specific in the assessment of intestinal DIE. Considering the possibility that DIE ultrasonography (rectal and/or vaginal ultrasonography) might be more accurate, we designed this study to assess this study to evaluate the accuracy of DIE ultrasonography.

Materials and Methods: In this retrospective cross-sectional study, we designed and conducted this study from 2019 to 2020 on patients suspected of severe endometriosis. Our patients underwent ultrasonographic imaging and based on the results became candidates for surgery. We compared histopathological results with sonographic findings using crosstabulation and chi-square tests were used to measure accuracy. $P < 0.05$ were considered statistically significant.

Results: Following pathological assessments of 109 cases, 97 cases had ovarian endometrioma, 42 cases had intestinal involvement and 56 cases had uterosacral DIE. The results for accuracy were as the following; uterosacral ligament (USL) involvement SE: 96.4% and SP: 59.1%; intestinal involvement SE: 97.6% and SP: 73.8%; and Cul de sac involvement with SE: 100% and SP: 50.8%. With regards to ovarian endometrioma, ultrasonographic imaging was 99.0% sensitive and 84.6% specific. With regards to intestinal involvement, ultrasonography performed a reliable overall diagnosis (97.6% sensitive and 73.8% specific). However, the results showed lower accuracy regarding the level of intestinal involvement. The accuracy for other sites and cavities was low except for ovarian endometrioma.

Conclusion: The results of the present study demonstrated that pre-operative TVS and Transrectal ultrasound (TRUS) can be a helpful paraclinical tool in the assessment and diagnosis of DIE and endometriosis in general and particularly with adnexal and bowel lesions, it can have some shortcomings with respect to cul de sac and USLs.

Keywords: Laparoscopic Surgery, Ovarian Endometrioma, Ultrasonographic Imaging

Citation: Asgari Z, Farzadi S, Hosseini R, Hadizadeh A, Mortezaazadeh M. Assessing the role and accuracy of ultrasonographic imaging in the diagnosis of deep infiltrating endometriosis: a cross-sectional study. *Int J Fertil Steril.* 2022; 16(4): 263-267. doi: 10.22074/IJFS.2021.535199.1167.

This open-access article has been published under the terms of the Creative Commons Attribution Non-Commercial 3.0 (CC BY-NC 3.0).

Introduction

Endometriosis is described as the presence of endometrial tissue in a space outside of the uterus and endometrial cavity. This disease affects almost 10% of women of reproductive age and is usually diagnosed with clinical history as most of the cases complain of chronic pelvic pain (1, 2). The average interval between the start of symptoms and surgical diagnosis is 10.4 years (3). Beyond the clinical symptoms and physical examination, imaging is the modality for the initial assessment of these patients. Imaging techniques currently used to diagnose endometriosis are magnetic resonance imaging (MRI)

and ultrasonography with a preference for sonography in recent years (4).

However, the combination of transvaginal sonography (TVS) and MRI is not recommended for a more accurate diagnosis (5). But still, other causes such as fibroma, corpus luteum, cystadenoma, tubo-ovarian abscess, teratoma, and carcinoma are needed to be ruled out (6-8). Identification of the endometriotic nodules and their correct localization enables complete lesion mapping before surgery and prevents unexpected plan changes in surgery (1, 6, 9, 10).

Deep infiltrating endometriosis (DIE) is recognized as

Received: 03/August/2021, Accepted: 11/December/2021

*Corresponding Address: P.O.Box: 1598116539, Department of Obstetrics and Gynecology, Arash Women Hospital, Tehran University of Medical Sciences, Tehran, Iran

Email: sara_farzadi800@yahoo.com



Royan Institute
International Journal of Fertility and Sterility
Vol 16, No 4, October-December 2022, Pages: 263-267

the most severe form of endometriosis has a complex clinical approach; it is described as a lesion that penetrates >5 mm under the peritoneal surface (11). DIE accounts for 15 to 30% of all endometriosis cases of which 90% are characterized by chronic pelvic pain and infertility, and 25% are accidentally discovered during laparoscopy or laparotomy (12, 13). DIE nodules infiltrate mostly the uterosacral ligaments (USL), rectosigmoid, vaginal fornix, rectovaginal septum, and/or bladder (14).

Intestinal endometriosis comprises a spectrum from simple adhesions between the intestine and cervix to nodular lesions that might involve serous membrane to the mucosa. These kinds of severe involvements require simultaneous cooperation between the colorectal and the gynecology surgeons. Due to various diameters and involvement stages, several surgical approaches have been proposed and used (1, 9). While smaller, less invasive, lesions are removed using stapled trans-anal resection, the larger and more invasive ones need segmental resection (6, 15).

A precise consensus on the definition and severity of endometriosis isn't reached yet but the most frequently used classification is the American Society of Reproductive Medicine (ASRM) classification; however, it fails to completely represent DIE's characteristics (16, 17). It's suggested that TVS is 79% sensitive and 94% specific in the assessment of the extent of DIE (2) meanwhile, it is proposed that DIE pelvic ultrasonography, which includes rectal and/or vaginal ultrasonographic imaging, is more accurate regarding the extent and severity (1, 2, 6, 11).

We designed and conducted this cross-sectional study to assess the accuracy of DIE ultrasonography and to do so, we compared the results with pathological and surgical findings, particularly with results of rectal involvement. It's suggested that TVS is 79% sensitive and 94% specific in the assessment of intestinal DIE. In this study, we assessed the accuracy of DIE ultrasonography (rectal and/or vaginal ultrasonography) which is thought to be more accurate.

Materials and Methods

We designed and conducted this cross-sectional study on patients with severe endometriotic symptoms who were a candidate for laparoscopic surgery and their disease was later confirmed histologically from December 2019 to December 2020. Our patients who were suspected of DIE were assessed in regards to the following characteristics and variables: age, body mass index (BMI) category, confirmed DIE or ovarian endometrioma (OMA), and the respective location and the level of involvement. Our patients were 35.41 years old on average with a standard deviation of 5.94. The symptoms included pelvic pain, dysmenorrhea, dyspareunia, infertility, abnormal uterine bleeding (AUB), and dysphasia. The patients were enrolled from the laparoscopic office of Arash hospital at Tehran university of medical sciences. Our exclusion criteria included the patients who were pregnant, menopausal, or had a non-endometrial mass

in adnexa, or other malignancies. We also excluded any patients who had any contraindications from the surgery. The patients who were of reproductive age and had a typical medical history compatible with endometriosis were also assessed, and if their imaging and pathological findings were consistent, they were included in the study. All patients included in the study provided informed consent. In this study we considered pathologically approved surgical results as our gold standard; thus, all our data was compared and tested with surgical findings confirmed by pathology. All patients were assessed by both the attending professor and the fellowship trainees, and all data relating to endometriosis such as pelvic pain, dysmenorrhea, dyspareunia, infertility, and AUB dysphasia were collected.

All the features and data gathered from ultrasonographic imaging along with surgical and pathological findings were collected, recorded, and analyzed. The patient's intestinal involvement was scored from 0 to 3 (0 being no involvement and 3 being full mucosal involvement). Other anatomical sites and areas such as adnexa, cul de sac, USLs, and the salpinx were also assessed and compared. We also gathered general body statistics of the patients and assessed the accuracy using the aforementioned data.

Based on the assumption from previous studies that DIE ultrasonography is up to 96% sensitive we calculated that our minimum cases should include 70 patients (Cochrane's sample size formula). In total, 109 cases were chosen for the study, and the data were analyzed using IBM's SPSS v26 software (IBM, USA). Our primary goal was to assess the sensitivity, specificity, and positive predictive value of DIE ultrasonographic examination particularly in the extent of intestinal involvement. We also used cross tabulation and chi-square tests to assess the significance of the tests.

This study was ethically approved by the Ethical Committee of the Tehran University of Medical Sciences (IR.TUMS.MEDICINE.REC.1399.936) and all patients had signed informed consent forms.

Results

In total, 150 cases with symptoms were chosen and 109 cases had either DIE or OMA, and 41 were not chosen due to no findings in ultrasonography. As reported by the pathology laboratory, there were 97 cases of pathologically confirmed ovarian endometrioma, 42 cases had intestinal involvement, 56 had uterosacral DIE, 19 cases had uterus adenomyosis and 9 cases were diagnosed with myoma. We also asked the patients to evaluate and score their symptoms from 0 to 10 and on average; The main symptoms that patients complained of were pelvic pain (80.3%), dysmenorrhea (85.3%), dyspareunia (48.6%), dysphasia (43.1%), AUB (29.4%) and infertility (29.4%) respectively (Fig.1). The symptoms were scored as follows; scored as the following dysmenorrhea at 6.74, dyspareunia at 3.36, and dysphasia at 2.72 respectively.

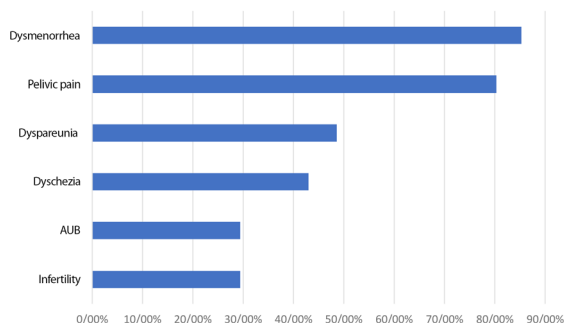


Fig.1: Proportion of each symptom felt by patients.

In regards to the accuracy of ultrasonography imaging in the diagnosis of intestinal DIE, which was our primary outcome, we found that ultrasonographic imaging performed excellently in overall diagnosis since it was 97.6% sensitive and 73.8% specific. However, laparoscopic evaluation was far more diagnostic (97.6% sensitive and 97.2% specific). As for the levels of involvement in the intestine, we compared the ultrasonographic imaging findings with pathologic results and the results showed lower accuracy; 55.6, 50.0, 66.7% sensitive, and 72.0, 85.6, 91.5% specific for serous membrane, muscular layer and mucus membrane respectively. The average BMI was 24.7 and most of the cases were in the normal range (46.3%) (Tables 1, 2, Fig.2).

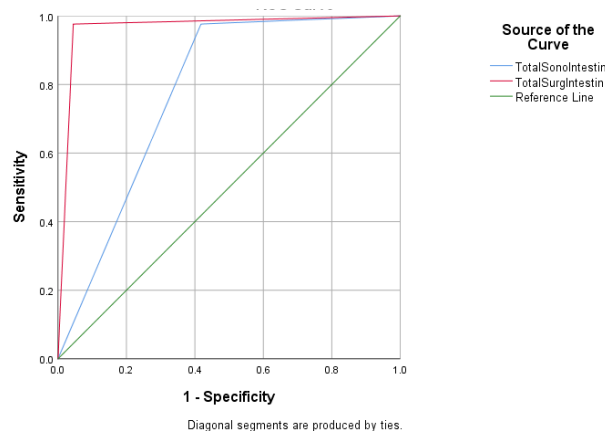


Fig.2: ROC curve diagrams showcasing the accuracy of DIE sonography and laparoscopy in regards to intestinal involvement. ROC; Receiver operating characteristic and DIE; Deep infiltrating endometriosis.

We also assessed the effect of obesity and weight on US imaging; we compared the results of US imaging of the intestine in 4 BMI brackets as follows: underweight (BMI<18.5), normal range (18.5 to 24.9), overweight (25 to 29.9), and obese (BMI>30). The results showed that both sensitivity and specificity were negatively affected. These results were statistically significant except for the underweight BMI bracket, which we believe was due to the small sample size (Table 3).

Table 1: Diagnostic accuracy of DIE ultrasonography and laparoscopy in diagnosis of DIE and endometrial lesions

Accuracy assessment	Sensitivity (%)		Specificity (%)		PPV (%)		NPV (%)	
	DIE US	Laparoscopy	DIE US	Laparoscopy	DIE US	Laparoscopy	DIE US	Laparoscopy
Intestine	97.6	97.6	73.8	97.2	59.4	93.2	97.1	95.5
OMA	99.0	99.0	84.6	88.0	88.0	78.0	97.1	88.0
Cul de sac	100	100	50.8	100	25.0	100	58.0	100
Uterosacral ligament	96.4	85.7	59.1	84.9	58	85.7	84.9	84.9

DIE US; Ultrasonographic imaging, PPV; Positive predictive value, NPV; Negative predictive value, and OMA; Ovarian endometrioma.

Table 2: Diagnostic accuracy of ultrasonographic imaging in regards to intestinal level of involvement

BMI (kg/m ²)	Sensitivity (%)	Specificity (%)	PPV (%)	NPV (%)	Chi square exact (P value)	Frequency n (%)	Fisher's exact test (P value)
BMI group I	100.0	80.0	75.0	100.0	0.071	8 (7.3)	0.071
BMI group II	94.7	70.0	66.7	95.5	<0.001	49 (45)	<0.001
BMI group III	93.8	61.0	55.6	87.5	0.037	35 (32.1)	0.037
BMI group IV	100	66.7	62.5	100	0.028	14 (12.8)	0.028

PPV; Positive predictive value, NPV; Negative predictive value, and BMI; Body mass index.

Table 3: The effect of body mass composition on accuracy of ultrasonographic imaging

Accuracy for assessment bowel layer	Sensitivity (%)	Specificity (%)	PPV (%)	NPV (%)	P value
Serous	55.6	72.0	39.5	83.1	0.009
Muscular	50.0	85.6	15.0	97.8	0.014
Mucus	66.7	91.5	40.0	93.3	0.003

PPV; Positive predictive value and NPV; Negative predictive value.

We also assessed the accuracy with respect to OMA and the DIE that infiltrates cul de sac and USLs. The results indicated that ultrasonographic imaging was 99.0% sensitive and 84.6% specific. The data of accuracy show that the examination for cul de sac was 100% sensitive, and 50.8% specific while it was 96.4% sensitive and 59.1% specific in assessing USLs. Although imaging is quite sensitive, it can be inaccurate regarding cul de sac and USL assessment since their positive predictive value was 25.0 % and 58% respectively; however, the results for ovarian assessment showed 92.3% PPV (Table 1).

Discussion

In our study, we identified that overall diagnostic accuracy was 97.6% sensitive and 73.8% specific. However laparoscopic evaluation was found to be far more accurate (97.6% sensitive and 97.2% specific). DIE was also found to lack accuracy in regard to the extent of involvement. It was also not accurate with respect to assessing cul de sac and USL. Imaging has always been an important tool in both the diagnosis and surgical approach to endometriosis. A thorough evaluation can help diagnosis and the entire approach and planning. Thus, it's of utmost importance that the data pertaining to the lesion is both accurate and reproducible, therefore we aimed to assess DIE ultrasonographic imaging as a complementary and multi-perspective imaging approach. DIE pelvic ultrasonography consists of vaginal and/or rectal US imaging (18). In a study conducted by S. Alborzi et al. (19), it was stated that ultrasonographic imaging (transvaginal or transrectal) is as accurate as MRI in the detection of lesions.

In our study, the diagnostic accuracy of ultrasonographic imaging in the identification of intestinal lesions, which was our primary outcome, was almost as high as laparoscopic evaluation. Therefore, we suggest that, in the overall diagnosis of DIE in the intestine, this procedure could be useful. In a multicenter prospective and retrospective cohort study conducted in the royal college of obstetrics and gynecology the accuracy of the preoperative ultrasound-based endometriosis staging system (UBESS) regarding the complexity of surgery was assessed; this study showed that US-based imaging can be utilized to plan the surgery (16).

We also assessed the accuracy of DIE US imaging with respect to other pelvic cavities and sites; in regards to ovarian endometrioma, we concluded that DIE ultrasonography can be a very efficient and accurate tool (99.0% sensitive and 84.6% specific) and as manifested by several other studies such as the study conducted by Holland et al. (16) can distinguish between different pathologies. Their study showed that TVS is an accurate assessment tool for the severity of pelvic endometriosis and the results are mostly in accord with laparoscopic findings. Meanwhile, we also studied the accuracy of DIE ultrasonographic imaging in the diagnosis of lesions located at USLs and cul de sac and concluded that even

though sensitivity for these lesions was high (100% and 96.4% sensitive for cul de sac and USLs respectively) the tests can be inaccurate as their PPV and specificity were low.

There were some limitations in our study that reduced the diagnostic accuracy of ultrasonography in DIE patients. We believe that ultrasound imaging accuracy could be hampered as poor bowel preparation can limit ultrasound wave penetration. On the other hand, the procedure itself (TRUS) is painful. These two can both limit the time required for investigation. Another reason that has led to lower accuracy could be the fact that linear nodules could be missed during laparoscopic surgery, particularly in cul de sac. we lacked sufficient samples for specific groups such as the patients with obese body composition.

In regards to the body composition of the subjects, we concluded that with higher BMI values the efficacy of US imaging plummets. As described by Bushberg et al. (20), due to fat impedance, 94% of the original sound wave is attenuated particularly in patients with more than 8 cm of subcutaneous fat before it even reaches the peritoneal cavity; hence, this phenomenon affects the acuity of ultrasonographic imaging.

Conclusion

Our study showed that while DIE pelvic ultrasonographic imaging can be a helpful paraclinical tool in the assessment and diagnosis of DIE and endometriosis in general and particularly with adnexal and bowel lesions, it can have some shortcomings with respect to cul de sac and USLs. We also suggest that in overweight patients these procedures should be performed more meticulously and probably in conjunction with other imaging methods such as MRI.

Acknowledgements

There is no financial support and conflict of interest in this study.

Authors' Contributions

Z.A., S.F.; Contributed to developing the research idea, composing, and revising the manuscript. R.H.; Contributed to composing and revising the manuscript. A.H., M.M.; Contributed to statistical analysis developing the research idea and revising the manuscript. All authors read and approved the final manuscript.

References

1. Parasar P, Ozcan P, Terry KL. Endometriosis: epidemiology, diagnosis and clinical management. *Curr Obstet Gynecol Rep.* 2017; 6(1): 34-41.
2. Berek JS. Berek and Novak's gynecology essentials. 1st ed. USA: Lippincott Williams and Wilkins; 2020.
3. Hadfield R, Mardon H, Barlow D, Kennedy S. Delay in the diagnosis of endometriosis: a survey of women from the USA and the UK. *Hum Reprod.* 1996; 11(4): 878-880.
4. Young SW, Groszmann Y, Dahiya N, Caserta M, Yi J, Wasson

- M, et al. Sonographer-acquired ultrasound protocol for deep endometriosis. *Abdom Radiol (NY)*. 2020; 45(6): 1659-1669.
5. Bazot M, Daraï E. Diagnosis of deep endometriosis: clinical examination, ultrasonography, magnetic resonance imaging, and other techniques. *Fertil Steril*. 2017; 108(6): 886-894.
 6. Halis G, Mechsner S, Ebert AD. The diagnosis and treatment of deep infiltrating endometriosis. *Dtsch Arztebl Int*. 2010; 107(25): 446-455.
 7. Turocy JM, Benacerraf BR. Transvaginal sonography in the diagnosis of deep infiltrating endometriosis: a review. *J Clin Ultrasound*. 2017; 45(6): 313-318.
 8. Kinkel K, Frei KA, Balleyguier C, Chapron C. Diagnosis of endometriosis with imaging: a review. *Eur Radiol*. 2006; 16(2): 285-298.
 9. Menakaya U, Reid S, Lu C, Bassem G, Infante F, Condous G. Performance of ultrasound-based endometriosis staging system (UBESS) for predicting level of complexity of laparoscopic surgery for endometriosis. *Ultrasound Obstet Gynecol*. 2016; 48(6): 786-795.
 10. Menakaya UA, Adno A, Lanzarone V, Johnson NP, Condous G. Integrating the concept of advanced gynaecological imaging for endometriosis. *ANZJOG*. 2015; 55(5): 409-412.
 11. Tosti C, Pinzauti S, Santulli P, Chapron C, Petraglia F. Pathogenetic mechanisms of deep infiltrating endometriosis. *Reprod Sci*. 2015; 22(9): 1053-1059.
 12. Ahn SH, Monsanto SP, Miller C, Singh SS, Thomas R, Tayade C. Pathophysiology and immune dysfunction in endometriosis. *Biomed Res Int*. 2015; 2015: 795976.
 13. Bulun SE. Endometriosis. *N Engl J Med*. 2009; 360(3): 268-279.
 14. Raiza LCP, Bianchi P, Cordioli E, et al. Prevalence of sonographic signs of deep infiltrative endometriosis amongwomen submitted to routine transvaginal sonography. *J Minim Invasive Gynecol*. 2016; 23(7): S27.
 15. Chapron C, Fauconnier A, Dubuisson JB, Barakat H, Vieira M, Bréart G. Deep infiltrating endometriosis: relation between severity of dysmenorrhoea and extent of disease. *Hum Reprod*. 2003; 18(4): 760-766.
 16. Holland T, Hoo W, Mavrellos D, Saridogan E, Cutner A, Jurkovic D. Reproducibility of assessment of severity of pelvic endometriosis using transvaginal ultrasound. *Ultrasound Obstet Gynecol*. 2013; 41(2): 210-215.
 17. Holland TK, Cutner A, Saridogan E, Mavrellos D, Pateman K, Jurkovic D. Ultrasound mapping of pelvic endometriosis: does the location and number of lesions affect the diagnostic accuracy? A multicentre diagnostic accuracy study. *BMC Womens Health*. 2013; 13: 43.
 18. Park SB, Kim JK, Cho KS. Sonography of endometriosis in infrequent sites. *J Clin Ultrasound* 2008; 36(2): 91-97.
 19. Alborzi S, Rasekhi A, Shomali Z, Madadi G, Alborzi M, Kazemi M, et al. Diagnostic accuracy of magnetic resonance imaging, transvaginal, and transrectal ultrasonography in deep infiltrating endometriosis. *Medicine (Baltimore)*. 2018; 97(8): e9536.
 20. Bushberg JT, Scibert JA, Leidholdt EM, Boone JM. The essential physics of medical imaging. 3rd ed. USA; Lippincott Williams and Wilkins; 2011.